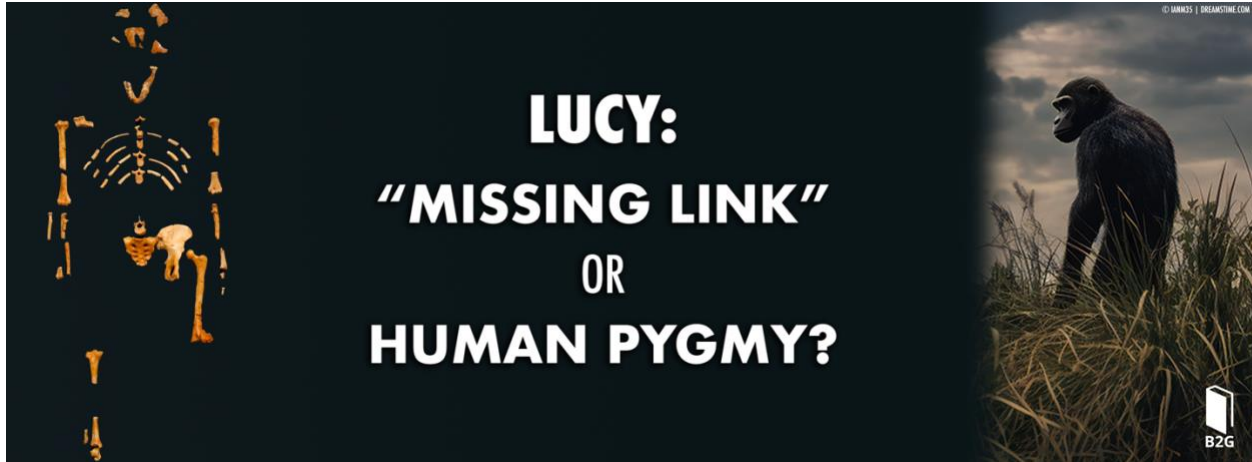

## “Lucy” and the Pygmy Human Hypothesis

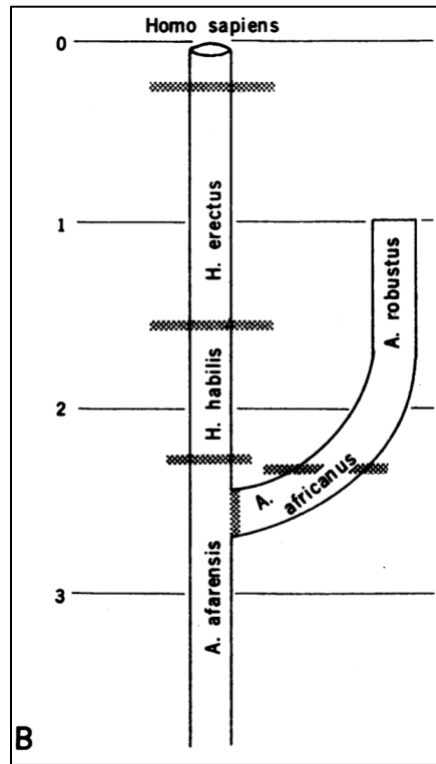
By Dr. Christopher Rupe

### Summary

There is a strong “group think” in the creation community that asserts “Lucy” and her kind, *Au. afarensis*, are an extinct quadrupedal ape. This group tends to overlook key diagnostic features indicating human-like obligate bipedality, which would contradict their position. Meanwhile, there is a growing number of dissenting voices that cannot help but acknowledge the presence of bipedal morphologies in the skeleton of Lucy and the broader *Australopithecus* genus. These “new creationists” argue Lucy’s kind had an ape-like cranium yet walked upright in a manner similar to modern humans. In this paper, several so-called “*Australopithecus*-like” traits are examined. Features commonly interpreted as indicators of arboreal propensities are found in small-bodied adult humans, such as the Flores “Hobbit” and in *H. naledi*. Since these same traits occur in humans, they cannot be considered diagnostic of *Australopithecus* taxa. This paper further identifies features in Lucy’s skeleton that are entirely consistent with *H. sapiens*. These findings call into question the taxonomic assignment of numerous human-looking fossils attributed to *Australopithecus*. Several lines of evidence support the hypothesis that Lucy was a genetically isolated small-bodied human, drawn from a pygmy population that lived in the Hadar region of East Africa, during the post-flood African Humid Period.

### The Rise of Lucy and the Prevailing Ape-to-man Model

Ever since Johanson’s announcement of the new species at the Nobel Symposium in Sweden in 1978,<sup>1</sup> “Lucy” and the species she is believed to represent, *Australopithecus afarensis*, has been promoted as the most likely root ancestor to the genus *Homo* (Figure 1). Over the past 50 years, few hominin discoveries have received more publicity than Lucy. The partial skeleton A.L. 288-1 is promoted as the quintessential “missing link” fossil in textbooks, museum displays, and popular science media outlets around the world. It is impossible to know how many souls have been led astray by the evolutionary interpretation of Lucy and her kind, perhaps there are many millions. Thus, clarity on the identity of Lucy bears eternal weight.



**Figure 1.** Johanson and White’s tree diagram with *Au. afarensis* positioned at the stem, representing the immediate ancestor to early *Homo* and all descendant species of the genus, including *H. sapiens*. From: Johanson and White (1979).<sup>2</sup>

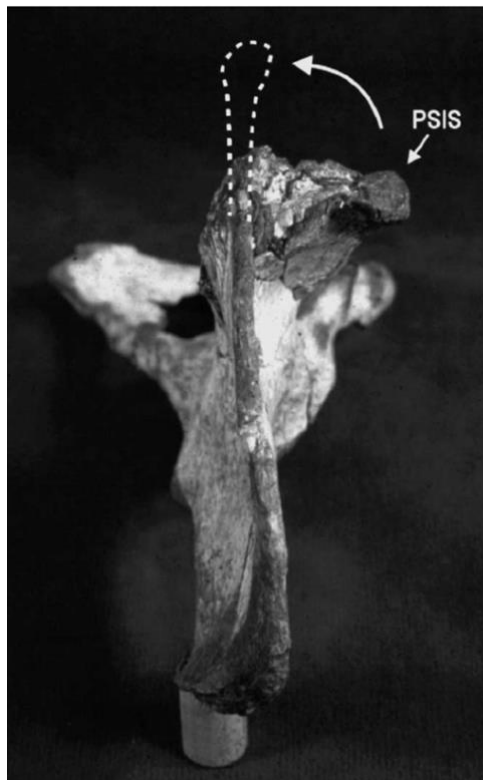Creationists have traditionally responded to these evolutionary claims by arguing Lucy is nothing more than an extinct ape.<sup>3-5</sup> This group of creationists either overlooks or downplays the purported bipedal morphologies in Lucy’s skeleton and in the broader genus. However, there is a growing number of “new creationists” and dissenting voices within the creation community who have recognized certain features that indicate bipedality.<sup>6</sup> These creationists have essentially conceded the evolutionary perspective that Lucy’s kind was an obligate biped with a human-like postcranial anatomy, perhaps with some arboreal traits, and an ape-like cranium. Other bizarre theories have been proposed that are largely ignored.<sup>7</sup>

Until now, creationists have never seriously considered the possibility that Lucy was a small-bodied human. This is puzzling since most of Lucy’s unique features that are argued to be “*Australopithecus*-like”—e.g., limb proportions, curved fingers and toes, laterally flaring ilia, etc.—are present in the small-bodied adult human from the Indonesian island of Flores, and to a lesser extent, in *H. naledi* (discussed below). This paper discusses several lines of evidence that support the interpretation that Lucy was a genetically isolated small-bodied adult human, drawn from a pygmy population that lived in the Hadar region of East Africa, during the post-flood African Humid Period.

This interpretation doubts there are additional primate fossils accidentally included as part of Lucy’s skeleton beyond the single baboon vertebra.<sup>8</sup> However, due to the discovery of additional Lucy bones during the few weeks of excavation that followed the initial discovery,<sup>9</sup> this possibility should not be discounted until a thorough bone-by-bone examination of Lucy’s skeleton is conducted (see Appendix).

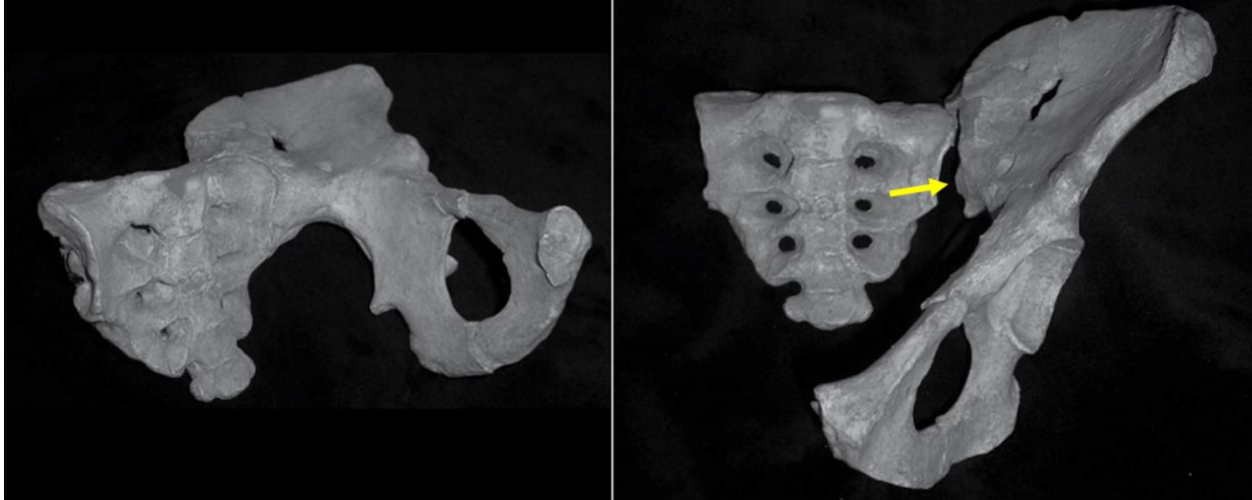
## Lovejoy's Reconstruction of Lucy's Ilium Was Not Fraudulent

There is a popular PBS Nova clip that shows evolutionary anatomist, Owen Lovejoy, using a grinding saw to correct the damage on Lucy's ilium.<sup>10</sup> This clip has been played and replayed by many creationists as Christian audiences laugh at the sight of Lovejoy grinding the plaster replicas to "reshape" the ilium the way he wanted to promote Lucy as a credible "missing link" fossil. The allegation that creationists have made is that Lovejoy fraudulently reconstructed Lucy's iliac crest to make it appear more like a human, and he allegedly did so in full view of millions of viewers during a major television broadcast. It has been argued that the unreconstructed ilium (before the grinding saw) looked a lot more like a chimp with coronally oriented ilia, as opposed to more sagittally oriented, like in humans.



**Figure 2.** Lucy's unreconstructed iliac crest is viewed from above (superior view). Lovejoy (2005) describes the fossil damage: "While much of the iliac blade is well preserved, the posterior third has been crushed, crumpled, and bent anterolaterally almost 90°." The damaged portion includes the auricular surface that joins to the sacrum. From: Lovejoy (2005).<sup>11</sup>

The allegations of deliberate fraud do not stand up to scrutiny. Fossil casts of Lucy's os coxa with the unreconstructed portion of the ilium can be purchased online. Anyone who has examined it will immediately recognize why it was necessary for Lovejoy to reconstruct the sacroiliac joint.<sup>11</sup> That part of the ilium is badly damaged (Figure 2), and obviously so—when one fits it to the sacrum, it rotates the os coxa such that the ischium ("sit bone") and pubis point straight out from the body and perpendicular to the sacrum, which is an anatomical absurdity (Figure 3, left). It is only in this obviously incorrect position that the iliac blades lay flatter, superficially, like that of a chimp. The "artificial joint" that formed as a result of the damaged sacroiliac joint has been described elsewhere by Johanson.<sup>12</sup>



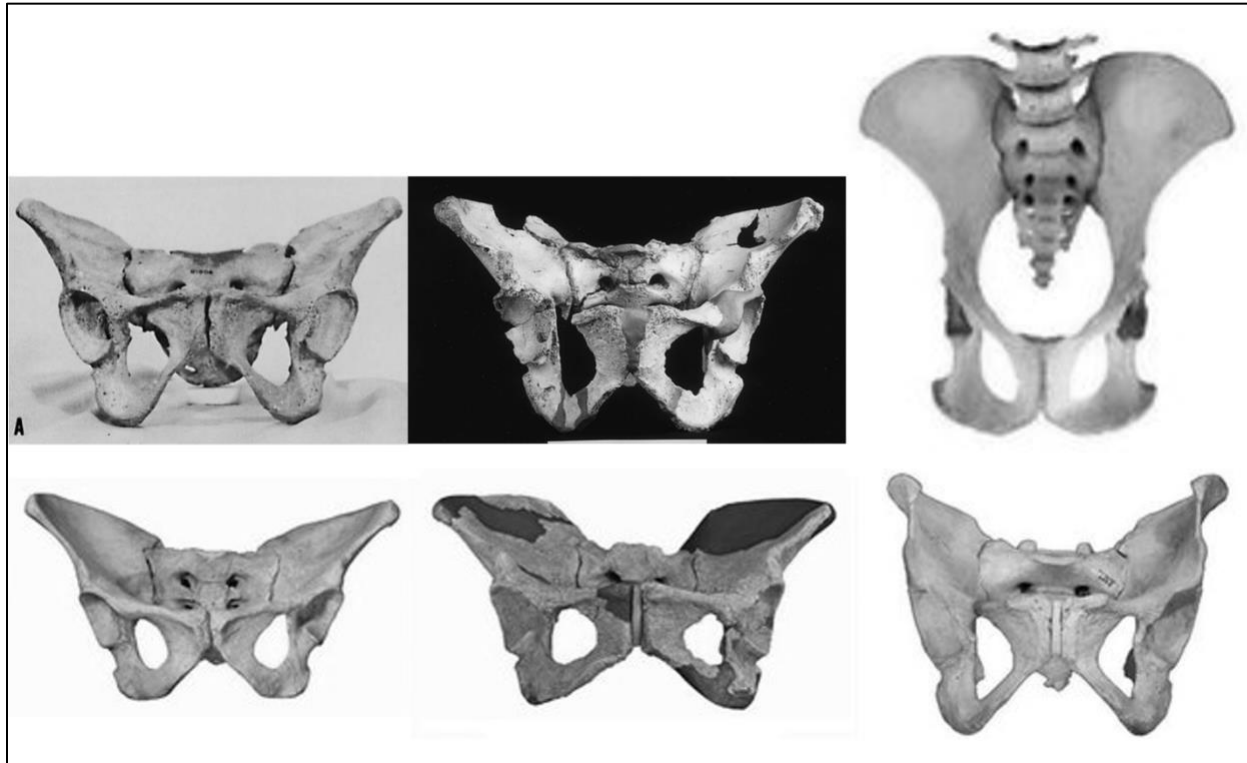
**Figure 3.** Lucy's sacrum joined together with the false joint of the ilium rotates the os coxa outward into an impossible orientation (left). When left uncorrected, there is a small gap between the sacrum and the auricular surface of the ilium (right; arrow). From: M. Murdock (2006).<sup>7</sup>

### **Diagnostic Features Confirm the Human Morphology of Lucy's Pelvis**

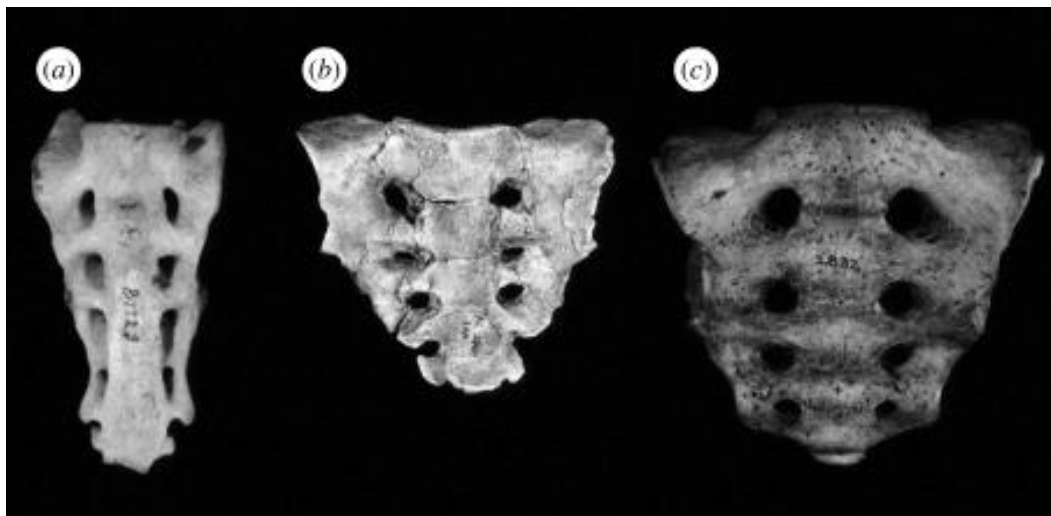
The damaged area of the sacroiliac joint was restricted to the posterior third of the ilium, immediately surrounding the auricular surface, and so Lovejoy's reconstruction could not have changed the overall shape of the pelvis. This is because the overall morphology of the pelvis is determined by several parts, and not just the sacroiliac joint—including the sacrum, ischium, pubis, and the larger, better-preserved part of the ilium. The integration of all these parts forms a distinctly human-looking pelvis—it is short, broad, and bowl-shaped—looking nothing like the long, flattened pelvis of a chimpanzee (Figure 4).

Lovejoy's restoration did not alter the sacrum, which was found intact and well preserved with only slight distortion. The sacrum of primates is morphologically distinct from humans. A photo atlas of non-human primates reveals their characteristic narrow, elongated shape.<sup>13</sup> The shape of Lucy's sacrum is shorter and wider, consistent with humans and distinctly different from chimps (Figure 5).<sup>14</sup>

The ilium itself is also morphologically human. Even accounting for the damaged region to the ilium, the dimensions reveal it is wider than it is tall, which is unique to humans and the reverse of apes.<sup>15</sup>

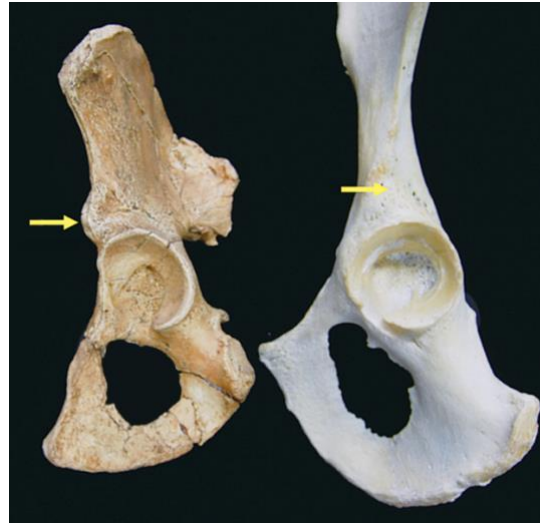

**Figure 4.** Top row: American Indian, Neanderthal (SH 1) from the “Pit of Bones” site in Spain, and chimpanzee. Bottom row: Lucy (A.L. 288-1ao-an), *H. erectus* (BSN 49/P27), and modern *H. sapiens*. Lucy’s short, broad, and bowl-shaped pelvis looks distinctly different from chimpanzee. Notice the laterally flaring ilia in the American Indian and hominin *Homo* specimens.



**Figure 5.** Anterior view of sacra belonging to (a) chimpanzee (*P. troglodytes*), (b) Lucy (A.L. 288-1an), and (c) *H. sapiens*. The narrow, elongated sacrum of chimps is distinct from the shorter, wider sacrum of Lucy and modern humans. From: Lovejoy and McCollum (2010).<sup>14</sup>

In the undamaged part of the ilium, there is a bony prominence known as the anterior inferior iliac spine (AIIS). The AIIS is on the front of the ilium which anchors the quadriceps muscle in the front of the thigh, called the rectus femoris muscle, also known as the “kicking muscle.” It is critical for knee extension and hip flexion—the ability to lift our leg forward at the hip joint. It is used in walking, running, kicking, and raising the knees to walk up steps. The equivalent of the AIIS in apes is flat; a bony prominence is not found in any non-human primates. It is a diagnostic human trait, and it is well preserved in Lucy’s ilium (Figure 6). That part of the ilium (anterior border) was totally unaffected by Lovejoy’s reconstruction of the sacroiliac joint.



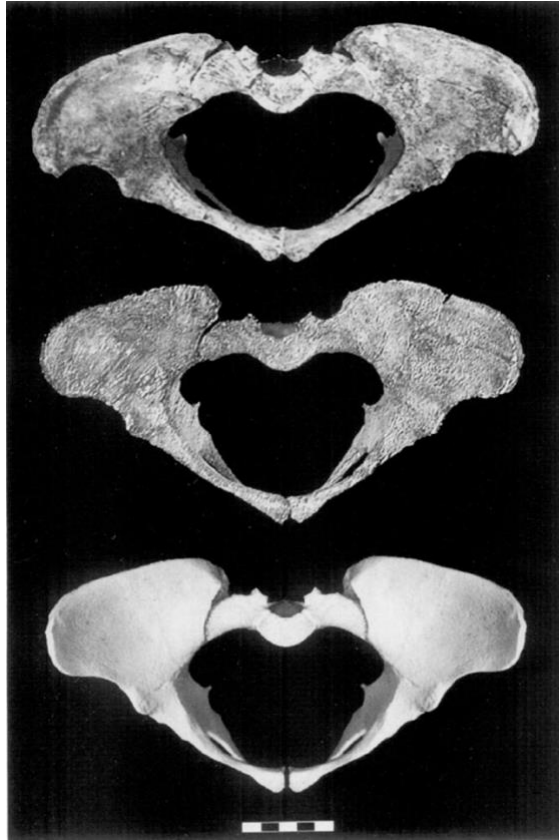**Figure 6.** Lucy’s os coxa preserves the bony prominence of the AIIS (left). The equivalent site is flat in chimps (right). From: [http://www.um.u-tokyo.ac.jp/UMUTopenlab/en/library/b\\_47.html](http://www.um.u-tokyo.ac.jp/UMUTopenlab/en/library/b_47.html)

### A “Blind” Reconstruction Corroborates Lucy’s Human Shaped Pelvis

Schmid (1983)<sup>16</sup> and Schmid and Häusler (1995)<sup>17</sup> did their own reconstructions of Lucy’s pelvis, and the overall shape did not dramatically differ from Lovejoy’s (1979).<sup>18</sup> It is distinctly human and not at all like a chimp. The pelvis is short, broad, and bowl-shaped in all three reconstructions.

The differences between the various reconstructions are subtle and mostly relate to the precise dimensions of the birth canal, as part of an obstetric analysis (Figure 7). Schmid and Häusler (1995) concluded that “Lucy” was a male, whom they nicknamed “Lucifer.” These researchers rejected the sexual dimorphism hypothesis proposed by Johanson et al. and argued Lucy’s kind, *Au. afarensis* represents “several distinct species which were previously jumbled together.” A debate within the paleoanthropology community on “gender confusion in the Pliocene” ensued.<sup>19</sup> Today, the consensus is that Lucy really was a female.

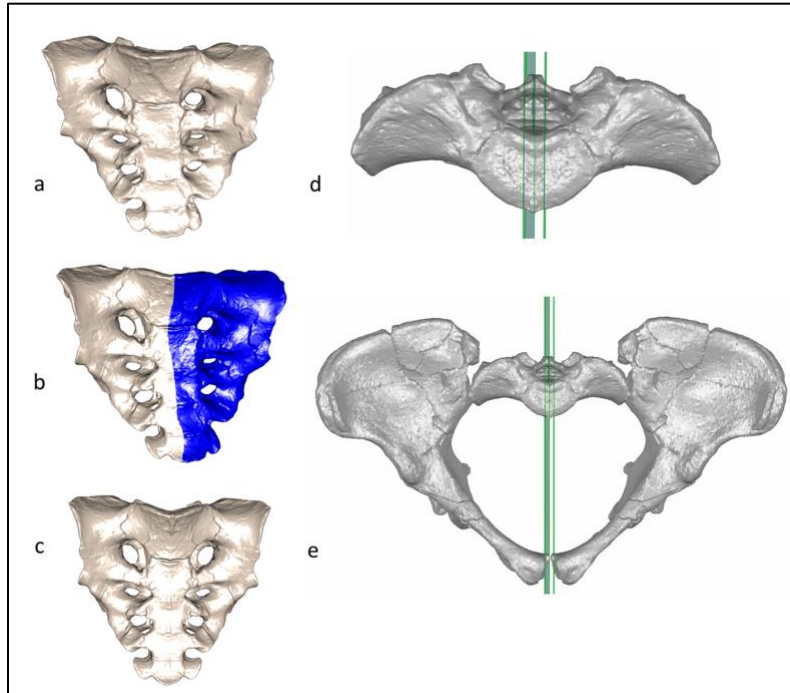
Regardless, this paper’s claim that Lucy’s pelvis is human does not hinge on any particular reconstruction since they all look distinctly human in morphology—nor does it depend on Lucy’s gender. The pelvises of neither male nor female chimps look anything like the short, broad pelvis of humans.



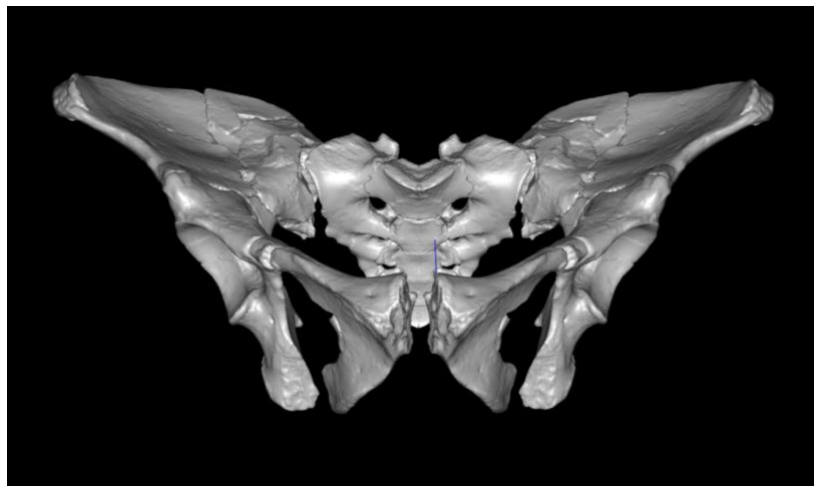
**Figure 7.** Reconstructions of the A.L. 288-1 pelvis. Top to bottom: Lovejoy (1979); Schmid (1983) (a preliminary version); and Schmid and Häusler (1995). Notice the consistency in the overall shape of the pelvis in these reconstructions. From: Schmid and Häusler (1995).<sup>17</sup>

A digital reconstruction of Lucy's pelvis was recently performed by Brassey et al. (2018)<sup>20</sup> (Figure 8 and 9). The original distortion to the sacrum was corrected to reveal its natural symmetry. In addition, the os coxa was reconstructed from its constituent pieces. These researchers commented that “there is definitely crushing of the sacroiliac joint,” however, they were able to reconstruct the pelvis without restoring the damaged part of the sacroiliac joint. This demonstrates that the human-like morphology of the pelvis does not depend on that part of the pelvis.

The overall human configuration of their reconstruction looks highly similar to the earlier reconstructions shown above. In fact, the co-author responsible for the reconstruction noted that he did so “blind” of the previous reconstructions to ensure an unbiased reproduction, yet he noted it happened to look remarkably similar to Schmid and Häusler's (1995).<sup>21</sup> In terms of overall morphology, all four look distinctly human and not at all like a chimp.



**Figure 8.** A digital reconstruction of Lucy's pelvis corrected the distortion to the sacrum and maintains the same overall morphology seen in previous reconstructions. The os coxa was mirror-imaged using the midline plane of the sacrum (green lines) as the reflection plane. From: Brassey et al. (2018).<sup>20</sup>



**Figure 9.** A “blind” reconstruction performed by O'Mahoney. Note the small gap between the auricular surface of the ilium and sacrum due to the unreconstructed sacroiliac joint. From: Brassey et al. (2017).<sup>22</sup>

### Lucy's High Bicondylar Angle

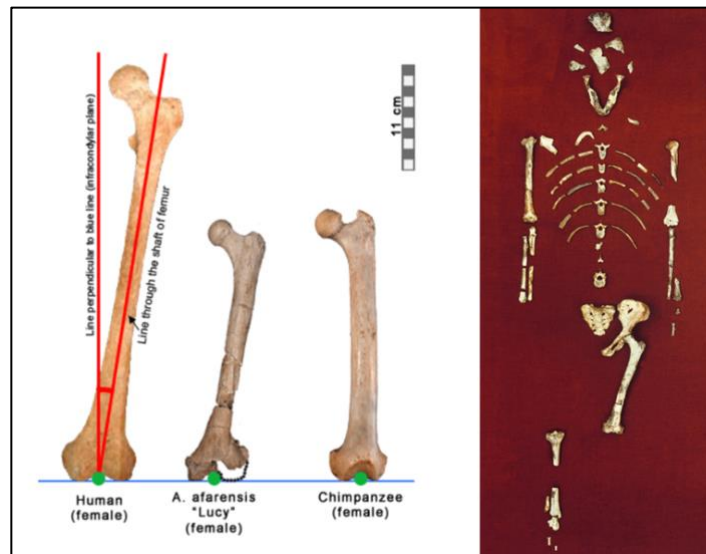
The bicondylar angle is the angle between the femur's shaft and a vertical line passing through the knee, perpendicular to the bicondylar plane. Some creationists have argued a high bicondylar angle is not a diagnostic feature when considered in isolation, since some primates have been shown to have higher bicondylar angles.<sup>23</sup> However, Miller and DeSilva (2023) note that the bicondylar angle measured in



humans is “at least one standard deviation above the largest angle seen among extant primates ( $5.3^\circ$  in *Macaca*).”<sup>24</sup>

Regardless of whether it should be considered diagnostic of human bipedality, when a high bicondylar angle occurs in combination with other features that are distinctly human, such as the morphology of the pelvis and/or femoral condyles (i.e., raised patellar lip, deepened patellar groove, and inferiorly flattened condyles), the bicondylar angle should count as a convincing corroborating evidence. The association of all those traits in a single distal femur is decisive evidence of human morphology and bipedality.

Lucy’s distal femur is damaged and does not provide an adequate lateral view of the condyles. However, Lucy’s wider sacrum and broader, bowl-shaped pelvis corresponds well with the higher bicondylar angle of her femur at  $12^\circ$  (compared to  $8\text{--}11^\circ$  in humans),<sup>25</sup> which places the center of gravity directly above her knees and feet, and closer to the midline of the body for stable bipedal locomotion (Figure 10).



**Figure 10.** Lucy’s high bicondylar angle falls within the human range. This feature combined with her human-shaped pelvis supports her true human identity. From: <https://iho.asu.edu/about/lucys-story>

### Lucy’s Morphological Similarities to the Small-bodied Human from Flores

When Johanson first brought the skeleton to show anatomist, Owen Lovejoy, who would be reconstructing the pelvis, he laid it all out on a table. Johanson asked, “You don’t think it’s a dwarf do you?” Lovejoy reassured him saying: “Nah, the skeleton doesn’t show any pathology. And what’s more,” Owen pointed to the leg bones, “these are about the same size as the knee joint from last year [A.L. 129-1]. I’ll bet you the females were small and the males were large.”<sup>26</sup>

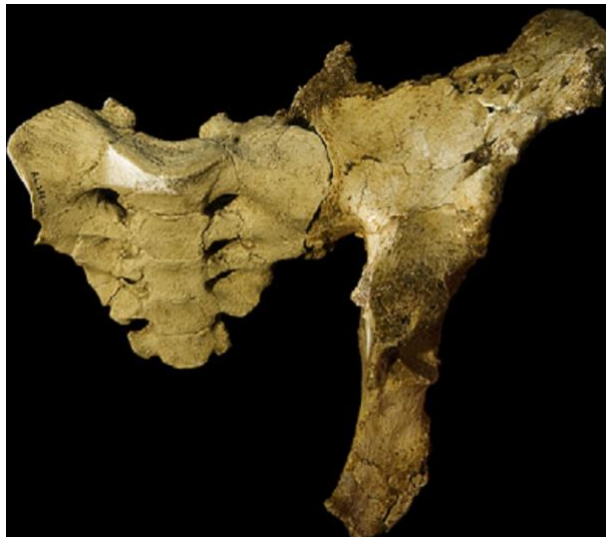Lovejoy’s response was interesting. He claimed that Lucy could not be a dwarf because the bones do not show any signs of pathology. That’s a good response to a question about dwarfism, but why didn’t they consider the possibility of a pygmy? Even today there are populations of small-bodied humans living in central Africa. Pygmies don’t suffer from dwarfism; they have naturally short stature and normal body

proportions. Anthropologists define pygmies as populations in which adult males are on average less than 4'11" in height; females are a little shorter so sexual dimorphism would not be dramatic. Males and females would both have small skeletons, and therefore small hips, small limbs, and small knee joints. Is it possible Lucy and other specimens from the Hadar formation belonged to a population of pygmies? There are several lines of evidence that demonstrate why the pygmy human hypothesis is not farfetched.

### ***The Pelvis of Lucy and Hobbit***

The late paleoanthropologist, William Jungers, from Stony Brook University, was astounded when Lucy's sacrum fit seamlessly with the sacroiliac joint belonging to the small-bodied human, *H. floresiensis*, from the Indonesian island of Flores (Figure 11). His reaction was recorded:

“Dr. William Jungers tries fitting a hobbit hip bone (ilium) to a cast of Lucy's tail bone (sacrum). To his surprise, they were a perfect fit. Lucy, the 3.2 million year old type specimen [correction: LH-4] for *Australopithecus afarensis*, from Ethiopia, was an early biped that stood just over a meter tall. The close match with a 17,000-year-old fossil in Indonesia is astounding.”<sup>27</sup>



**Figure 11.** Lucy's sacrum articulated with the os coxa of the small-bodied human from the Indonesian island of Flores. From: Jungers et al. (2009).<sup>28</sup>

The “perfect fit” makes sense when we recognize that Lucy was an adult small-bodied human (the sacrum shows the complete fusion of the five sacral vertebrae). *H. floresiensis* is also widely considered a small-bodied human by creationists and evolutionary paleoanthropologists alike. In fact, lead members of the discovery team,<sup>29</sup> among other paleoanthropologists,<sup>30,31</sup> have argued Hobbit was a pathologic or inbred modern human pygmy (*H. sapiens*).

Jacob et al. (2006) have claimed Hobbit was drawn from the Rampasasa pygmy population that still lives on the island not far from Laung Bau cave where Hobbit fossils were found. Pygmy populations are also thriving in the Congo Basin of Central Africa and may have lived in East Africa during the African Humid Period. And so, if both Lucy and Hobbit were small-bodied humans, it makes sense the two parts of the

pelvis would fit together. It's only puzzling if they belonged in entirely separate genera, with two very different locomotor behaviors, as creationists have traditionally insisted.

### ***The Limb Proportions of Lucy and Hobbit***

The limb proportions can be a useful proxy for distinguishing extant apes and humans, including fossil hominins. The limb proportions of the small-bodied human, LB 1, are reported in the scientific literature as a humeralfemoral index value (100 x humerus length/femur length). The humerus and femur length for LB 1 are 243 mm and 280 mm, respectively, yielding a humeralfemoral index of 86.8.<sup>32</sup> The humerus and femur length for Lucy are remarkably close, 239 mm and 280 mm, respectively, yielding an index of 85.4 mm.<sup>33</sup>

The humerus length of Lucy is “within the range for human pygmies” whereas the femur is shorter than modern pygmies.<sup>34</sup> Keep in mind, however, the femur in A.L. 288-1 is missing a segment and so estimates vary from 277-286 mm in length.<sup>35</sup> If the upper estimate is used, the humeralfemoral index value would be lower, yet only slightly closer to human pygmies living today. In either case, the limb proportions of the small-bodied human LB 1 and Lucy are identical within a margin of error. Height estimates (stature) are also virtually identical (1.05 m).<sup>36</sup>

### ***The Thorax Shape of Lucy and Hobbit***

It is often assumed that Lucy had a conical or funnel-shaped thorax, as in apes. This may be the case however, it depends on the reconstruction. Some paleoanthropologists argue Lucy's thorax was more barrel-shaped, as in anatomically modern humans. The latest reconstruction shows a more human-like barrel-shaped thorax.<sup>37</sup> The fact that paleoanthropologists have a fundamental disagreement on this is not surprising. It may not be something that can be conclusively determined due to its fragmentary condition. Brassey et al. (2023) acknowledge this, stating:

“The subject of the shape of the *Australopithecus* thorax has been one of considerable debate (Schmid, 1983; Lewin and Foley, 2004; Haile-Selassie et al., 2010a, b; Schmid et al., 2013; Latimer et al., 2016). Both a human ‘barrel shape’ and hominoid ‘funnel shape’ ribcage have been proposed for *A. afarensis*, with previous reconstructions being based on very limited fragmentary remains.”<sup>38</sup>

The fragmentary condition of the thorax explains why anatomists cannot confidently identify Lucy's rib numbers, aside from the first rib. Ironically, the only identifiable rib is described as looking distinctly like those of *H. sapiens* and different from what is observed in all non-human primates.<sup>39</sup>

Regardless, all of this misses the point since humans have been shown to have funnel-shaped thoraxes, including the pygmy human from Flores, the small-statured *H. naledi*,<sup>40</sup> Neanderthals,<sup>41</sup> Turkana Boy,<sup>42</sup> and pathologic modern humans.<sup>43</sup> So, even if Lucy's thorax were funnel-shaped, it cannot be considered diagnostic of *Australopithecus* nor apes. Instead, it could arguably count as yet another unique feature shared by the pygmy human from Flores. Interestingly, both the Flores pygmy and Lucy have laterally flaring ilia, which would correspond well with a “slightly” flared lower thoracic cage.<sup>44</sup>

### ***The Endocranial Capacity of Lucy and Hobbit***

The A.L. 288-1 cranium is highly fragmentary (Figure 21). Only six fragmentary pieces are preserved (A.L. 288-1a = occipital fragment, 1b = left parietal fragment, 1c/g = biparietal fragment, 1d = left zygomatic fragment, 1e = parietal fragment, 1h = right frontal fragment), which do not reveal any key diagnostic features of the skull, such as the foramen magnum placement/orientation. Since most of Lucy's cranium is missing, her endocranial capacity cannot be directly measured.<sup>45</sup>

Estimates can range between 365-417 cc, and are typically modeled based on ape endocranial capacities, in keeping with the evolutionary preconception that human-like bipedality evolved before big brains.<sup>46</sup> As a result, Lucy's endocranial capacity may be underestimated. Regardless, the upper estimate cited above is approximately the same as the pygmy human from Flores (380-426 cc),<sup>47,48</sup> and so, it is entirely possible Lucy's cranium belonged to an adult, small-bodied human.

### **Summary of Unique Features Shared by Lucy and Hobbit**

Lucy and Hobbit have several unique features in common including flat-footedness,<sup>49,50</sup> curved fingers and toes,<sup>51</sup> nearly identical endocranial capacities, virtually identical limb proportions, nearly identical height, broad pelvises with laterally flaring ilia,<sup>52</sup> non-projecting chins, and possibly more funnel-shaped thoraxes with higher positioned scapulae. The commonality of all these aberrant features makes sense if both belonged to small, genetically isolated pygmy human populations.

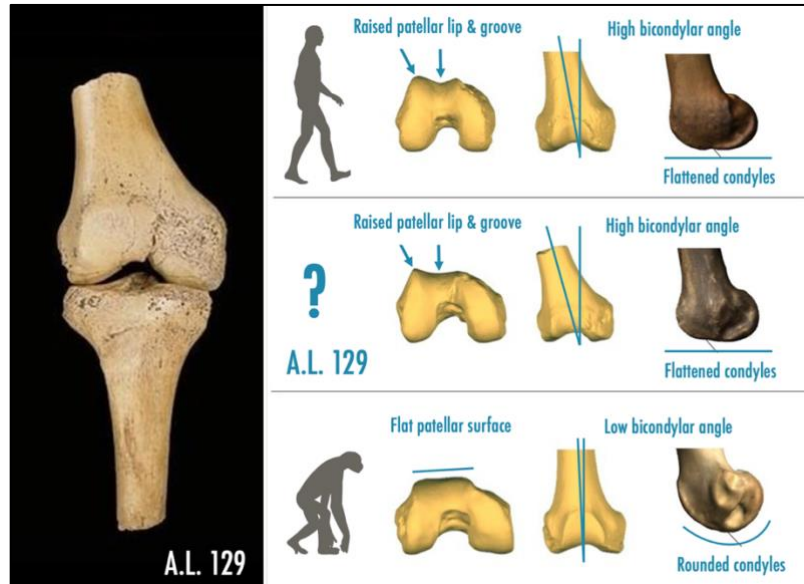
Several of these reputed “*Australopithecus*-like” features are also found in *H. naledi* specimens from South Africa<sup>53,54</sup>—as well as in pygmy humans from Palau, Micronesia.<sup>55</sup> Apparently, the same suite of traits can arise independently in geographically separated populations, which indicates they are likely developed by similar processes. Perhaps parallel processes include genetic isolation, insular dwarfism, inbreeding, and fixation events associated with founder effects, just as evolutionary paleoanthropologists have proposed.<sup>56</sup>

### **Further Evidence of a Post-flood Pygmy Human Population in East Africa**

The human pygmy hypothesis is further supported by the small A.L. 129-1 knee joint that was discovered by Johanson during his first International Afar Research Expedition, a year before he found Lucy, at an entirely separate locality.

A high bicondylar angle (15°) is visually apparent in the A.L. 129-1 specimen (Figure 12). The distal part of the femur preserves inferiorly flattened condyles that are elongated in lateral view. This feature is both measurably and visually distinct from apes.<sup>57</sup> Inferiorly flattened condyles are critical for increasing the contact surface in the knee joint for load dissipation. Apes have inferiorly rounded condyles, which is why they cannot stand upright in a restful, lock-kneed position. In addition, the patellar groove is deep and there is a raised lateral patellar lip, which is typical of modern humans and necessary to prevent patellar dislocation when associated with a high bicondylar angle.<sup>58</sup>

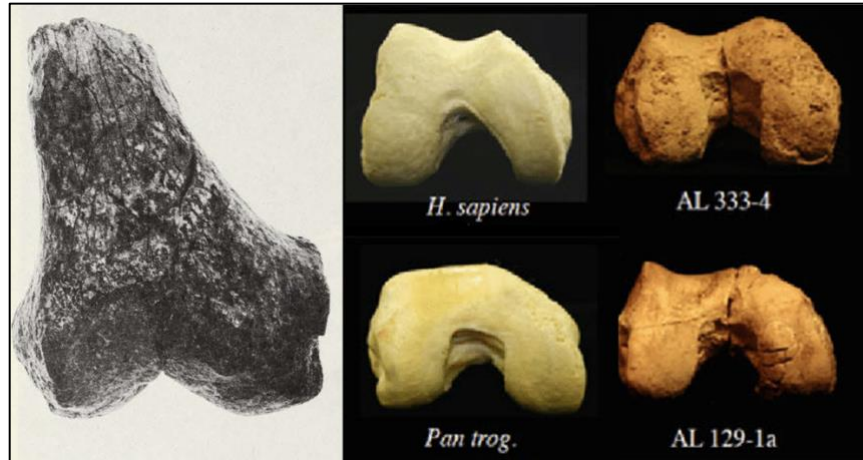The presence of all of these traits together in one knee joint—i.e., high bicondylar angle, raised lateral patellar lip, deep patellar groove, inferiorly flattened and laterally elongated condyles—is conclusive evidence of bipedality and modern human anatomy. Johanson and Taieb recognized these distinctly human features in their earlier *Nature* paper (1976).<sup>59</sup> Interestingly, this was the same paper where they originally reported their Hadar collection consisted of two separate genera, *Australopithecus* and *Homo*.



**Figure 12.** (Left) A.L. 129-1 knee joint exhibiting a high bicondylar angle. (Right) Inferior and lateral views of femoral condyles in *H. sapiens* (top row), A.L. 129-1a (middle row), and chimpanzee (bottom row). Adapted from: Miller and DeSilva (2023).

The complete fusion of growth plates confirms the knee joint belonged to an adult human of small stature, nearly identical in size as Lucy's. Thus, we now have evidence of two small-bodied individuals having lived in the same general vicinity of the Hadar region. Lucy is one individual and the second is the owner of the isolated knee joint found at Afar Locality 129. Apparently, there was a population of small-bodied humans living in Eastern Africa, sometime after the Flood.<sup>60</sup>

In this same Hadar formation, a distal femur was recovered from the “First Family” site (A.L. 333-4) during the 1975 field season. It is very similar in terms of overall morphology to the A.L. 129-1a distal femur, though noticeably larger in size.<sup>61</sup> The larger distal femur has all of the same diagnostic bipedal human features as A.L. 129-1a (Figure 13). Johanson and colleagues have attributed these large and small distal femora, as well as other homologous anatomical elements, to sexual dimorphism.<sup>62,63</sup> In reality, these particular distal femora reveal that humans of “normal” stature lived in the same region as small-bodied humans.



**Figure 13.** (Left) A.L. 333-4—a larger distal femur recovered from the “First Family” site displaying a high bicondylar angle. Right, clockwise: Femoral condyles of *H. sapiens*, A.L. 333-4, A.L. 129-1a, and chimpanzee (*Pan trog.*) A.L. 333-4 reveals a raised patellar lip and a deep patellar groove, as can be seen in A.L. 129-1a and *H. sapiens*. From: Schwartz (2014).<sup>64</sup>

### “Red herring” Traits Mislead Creationist’s Taxonomic Assignments

Below are a few examples of what may be considered “red herring” traits because they have led to the misclassification of several hominin fossils that preserve similar features. These examples demonstrate why it is so important for creationists to correctly identify key morphological features that can be used to distinguish extinct fossil apes and true *Australopithecus* fossils from humans. In my assessment, the real *Australopithecus* was an extinct ape, similar to extant great ape species (e.g., A.L. 444-2 and A.L. 822-1); and claims made about certain fossils displaying distinctly human-like bipedal morphologies is a tell-tale sign that those fossils may not belong to *Australopithecus* and careful reexamination is warranted. Thus, once all of the distinctly human fossils that were falsely attributed to *Australopithecus* are reclassified as *Homo* (not arbitrarily, but on the basis of key morphological indicators) what remain are the fossils of extinct members of the Hominidae family. This will further help to fill in the largely absent fossil record of African apes.

### *Funnel-shaped Thoraxes are Diagnostic of Australopithecus?*

A funnel-shaped thorax is typically regarded by creationists as a diagnostic feature of *Australopithecus* taxa. This has led to the misclassification of *H. naledi* as *Australopithecus* largely on the basis of thorax shape.<sup>65</sup> However, as noted above, humans have been shown to have funnel-shaped thoraxes, including the pygmy human from Flores, Neanderthals, Turkana Boy, and pathologic modern humans. Since this feature is not unique to *Australopithecus*, and is found in humans, it is an example of a red-herring trait.

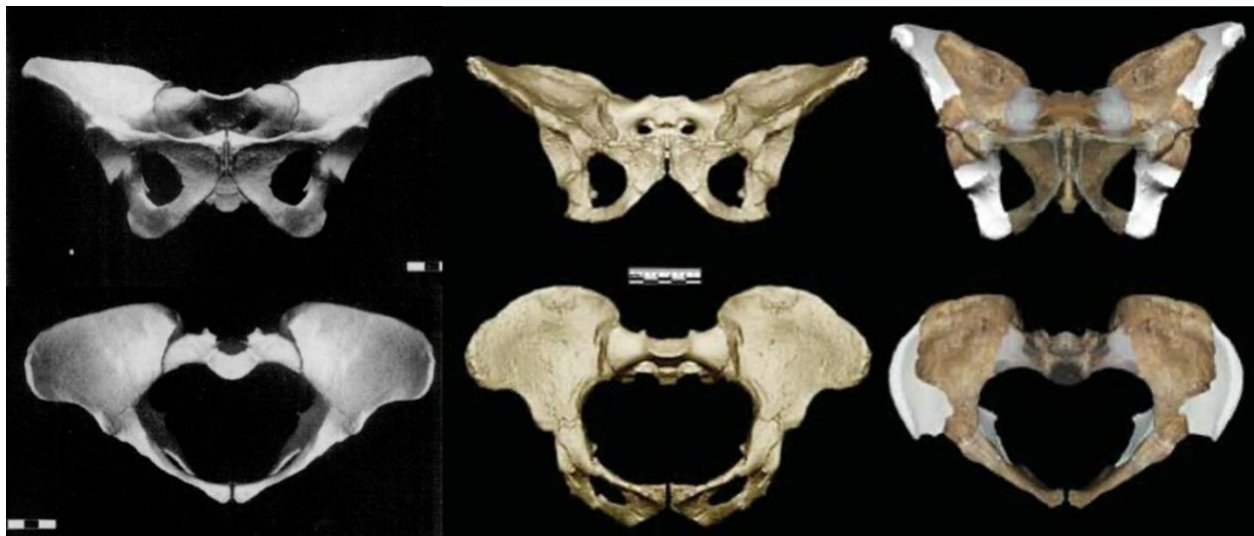
### *Laterally Flaring Iliac are Diagnostic of Australopithecus?*

Several *Homo* pelvises, including Native American specimens, Neanderthals (SH 1),<sup>66</sup> *H. erectus* (BSN 49/P27),<sup>67</sup> *H. floresiensis* (LB 1),<sup>68</sup> *H. naledi*,<sup>69</sup> and pathologic modern humans<sup>70</sup> exhibit laterally flaring

ilia (see Figure 4 above and Fig. 8 in Chapter 10 in *Contested Bones*). Additional examples of hominin *Homo* pelvises with laterally flaring ilia have been documented.<sup>71</sup> Clearly, this feature is not exclusive to *Australopithecus*. In fact, it may be argued that only human pelvises can have flaring ilia (apes have flat-lying iliac blades that do not flair laterally). *Australopithecus* pelvises with laterally flaring ilia are likely to be misclassified human pelvises. Regardless, some creationists have considered this feature diagnostic of *Australopithecus*. This red-herring trait has caused creationists to overlook the overall distinctly human form of these bowl-shaped pelvises.

The misclassification of Lucy's pelvis as *Australopithecus* has led to the misclassification of a series other hominin pelvises that look similar to Lucy's—a “domino effect” if you will. Consequently, when this trait is found in other hominins such as *H. naledi*, *Au. sediba*, or *Au. africanus*, creationists may be inclined to conclude those pelvises must therefore belong to *Australopithecus*. Indeed, some creationists have argued (at least in part) on the basis of flaring ilia, that *H. naledi* was an australopithecine-human hodgepodge.<sup>72</sup> This view is based on an evolutionary study<sup>73</sup> that noted the degree of lateral flaring in the ilia of STS 14 (*Au. africanus*), as well as A.L. 288-1 (Lucy) is similar to that of *H. naledi*—yet these authors miss the fact that this is simply because all three are human pelvises. STS 14 closely resembles Lucy's, in terms of morphology and size. It is another example of a misclassified human pelvis (Figure 14). Supporting this interpretation, the STS 14 pelvis was found with a human-shaped vertebrae column with lumbar lordosis. This specimen was misclassified by paleoanthropologists as *Au. africanus* (it was considered “too old” to qualify as *Homo*), a taxonomic designation that creationists have uncritically accepted.

This red-herring trait has also contributed to the acceptance of *Au. sediba* as a sound species with its pelvis attributed to the *Australopithecus* genus. In reality, the laterally flaring pelvis of *Au. sediba* is morphologically human and should be classified as such (Figure 14).

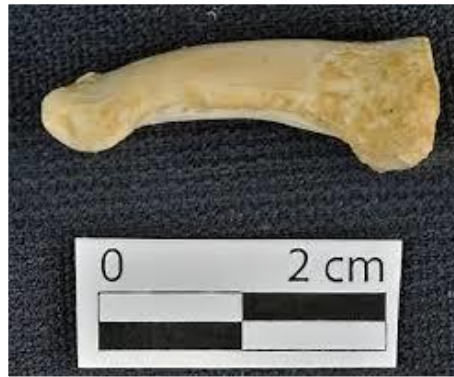

**Figure 14.** Misclassified human pelvises. Left to right: Lucy (A.L. 288-1); *Au. africanus* (STS 14); *Au. sediba* (MH 1/MH 2 composite). From Schmid and Häusler (1995); STS 14 and MH 2 from Kibii et al. (2011).

The failure of creationists to recognize true human pelvises in the *Australopithecus* genus has only helped to bolster the evolutionary narrative that the australopithecines, including Lucy, were obligate bipeds with human-like pelvises, yet with ape-like skulls—an “ideal” transitional form.

### ***Curved Fingers and Toes are Diagnostic of Australopithecus?***

Curved fingers and toes are yet another feature that has led creationists to misclassify human fossils as *Australopithecus*, such as those who have argued *H. naledi* is an *Australopithecus*.<sup>74</sup> Once again, curved fingers and toes should not be considered a diagnostic trait since it can occur in humans. For example, in 2019, finger bones belonging to another small-bodied human were discovered in Callao Cave on the Philippine Island of Luzon.<sup>75</sup> The finger bone was found together with other undisputed human bones. Like the small-statured *H. naledi*, the finger bones of the pygmy from Luzon are curved (Figure 15).



**Figure 15.** The upper profile of finger is curved like that of an ape, yet there can be no question it belonged to the small-bodied human, *H. luzonensis*. From: <https://www.donsmaps.com/luzon.html>

The Flores “Hobbit” was also found to have curved fingers (and curved toes). The hand bones belonging to the individual LB 6 were described by Kivell (2015) as follows: “...although *H. floresiensis* has a broad pollical distal phalanx with a human-like FPL attachment, the proximal phalanges are curved to a similar degree as in *Au. afarensis*...”<sup>76</sup>

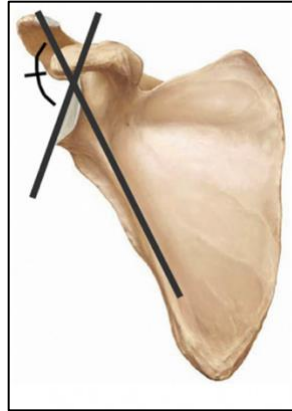
The author mentions the presence of a flexor longus pollicis (FLP) attachment at the base of the distal phalanx (thumb). In humans, the FLP is a long muscle in the forearm that extends through the carpal tunnel as a tendon to where it attaches to the base of the thumb, which allows us to flex our thumb. Apes lack the FPL muscle. The presence (or absence) of a well-developed attachment site is a more decisive taxonomic indicator than curved fingers alone. This feature is well-preserved in a thumb bone attributed to *Au. afarensis*, labeled A.L. 333-159. The researchers observe, “A distal pollical phalanx confirms the presence of a human-like flexor pollicis longus muscle in *A. afarensis*.”<sup>77</sup>

This more than likely represents yet another example of a misclassified human bone, which would make sense since it was found from the same “First Family” site where all the other misclassified human hand bones and human foot bones were found.<sup>78</sup> Again, this is the same fossil assemblage (site A.L. 333) that Johanson originally considered to be *Homo*.<sup>79</sup>



Thus, just as the misclassified pelvis of Lucy can create a “domino effect” of other misclassified pelvises, the same can happen with human hands that were misclassified as *Australopithecus*, especially when they are found in strata that allegedly date older than the genus *Homo*, such as the Hadar formation in Ethiopia.

### ***Cranially Oriented Glenoid Cavities are Diagnostic of Australopithecus?***



**Figure 16.** Bar-glenoid landmarks. From: Churchill et al. (2018).

Lucy preserves a small part of the scapula that articulates with the humerus to form the shoulder joint, known as the glenoid cavity. Paleoanthropologists study several scapular landmarks that may be used to infer the propensity for arboreal behavior. A more cranially orientated glenoid cavity is typically considered to be more ape-like, since it allows for habitual elevation of the arm, as would be used in climbing.<sup>80</sup>

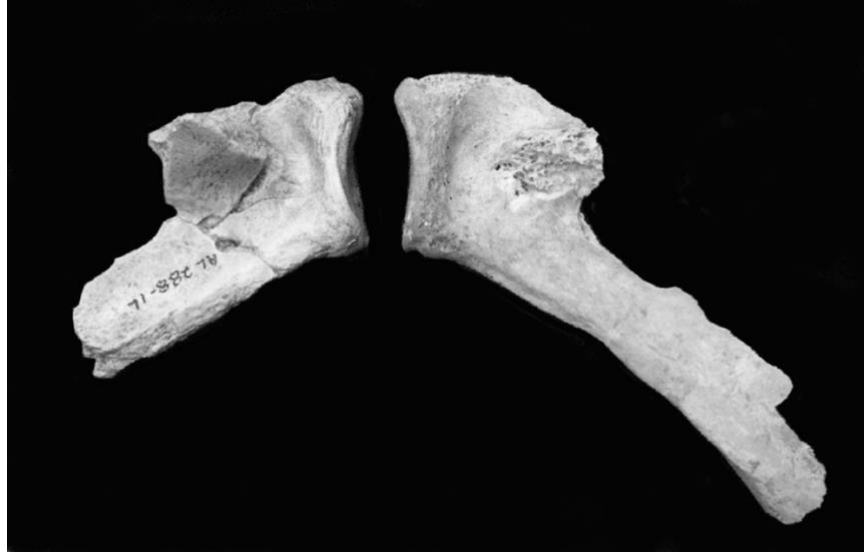The ventral/bar glenoid angle is one such feature commonly used to indicate arboreal behavior (Figure 16). Lower angles closer to 130° indicate a more cranially oriented glenoid cavity. Lucy’s bar-glenoid angle measures 132.3°, compared to 134.0° in “Big Man” (KSD-VP-1/1), 137.6° in “Turkana Boy” (KNM-WT 15000), 131.6° in *Au. sediba* (note that the scapula of MH 2 is verifiably human, not ape),<sup>81</sup> 142.3° in *H. sapiens*, 157° in the “Hobbit” (LB 6/4), 127.8° in chimps, and 130.6° in gorillas.<sup>82</sup>

A low bar-glenoid angle has been used to argue that Lucy had a more ape-like orientation of the glenoid cavity.<sup>83</sup> Even so, the bar-glenoid angle in MH 2 is nearly the same as Lucy’s; Big Man’s is also close to Lucy’s, which is consistent with this author’s perspective that all three are human scapulae. Lovejoy has noted in *Nature News* that Big Man’s “scapula, which anchors the shoulder muscles, is very similar to that of a modern human...”<sup>84</sup> If Big Man’s scapula is human, as the rest of the skeleton confirms, it logically follows that humans, including Lucy, can have low bar-glenoid angles, too. Yet, that doesn’t mean those scapulae belong apes.

In describing the bar-glenoid angle in Lucy, Haile-Selassie et al. (2010) make a fascinating observation relating to supposed scaling effects when they compared it to a small-statured human scapula:

“The “bar-glenoid” angle has been used to orient the glenoid plane in A.L. 288-1 (29), but the specimen’s small size may have had scaling effects (30, 31), an observation supported by the fact that its bar-glenoid angle can be matched exactly by comparably sized humans (SI Appendix, Fig. S21).”<sup>85</sup>

These researchers are both surprised and puzzled by the small-statured Amerindian’s bar-glenoid angle, which perfectly matches Lucy’s in her corresponding scapula fragment (Figure 17). Haile-Selassie et al. (2010) describe the striking similarity in the supplementary information of their published paper, stating: “The specimens from opposite sides have been aligned based on the orientation of their glenoid planes. Note the virtual identity of their bar-glenoid angles.”



**Figure 17.** The scapular fragment of A.L. 288-1 compared to an equally small-statured Amerindian's scapula with similar degree of preservation. From: Haile-Selassie et al. (2010).

All things considered, there can be a broad range in bar-glenoid angles (and glenoid-axillary angles) in humans. Indeed, researchers have found that among smaller sized scapulae, the bar-glenoid angle in arboreal species and humans overlap:

“We have found that the data scatters for the African apes and humans converge at the smaller size ranges, and Lucy's value for bar-glenoid angle is not tightly correlated with function and, as such, cannot be used as a morphological signal for arboreal behavior, especially in the smaller size ranges at which arboreal and nonarboreal species overlap.”<sup>86</sup>

The important question to consider is whether a more cranially oriented glenoid cavity can be considered a diagnostic taxonomic indicator, especially since lower angles are measured in human scapulae, such as Big Man, MH 2 (misclassified as *Au. sediba*), small-statured American Indian, *H. naledi*, and *H. erectus* specimens from Dmanisi, Georgia. When describing an adult scapula from Dmanisi, Lordkipanidze et al. (2007), observe: “The glenoid cavity [D4166] is more cranially oriented relative to the midaxillary border than in modern humans, and thus closer to the condition found in australopiths (Sts7 and AL288-1) and African apes.”<sup>87</sup>

Likewise, Feuerriegel et al. (2019) describe the glenoid cavity of a partial scapula from a small-bodied human from the Dinaledi Chamber as markedly cranially oriented:

“The Dinaledi Chamber preserves one partial scapula, U.W. 101-1301, with bar-glenoid and axillary border/spine angles indicative of a markedly cranially-oriented glenoid fossa and very oblique scapular spine, respectively (Feuerriegel et al. 2017). This scapula configuration is similar to what is seen in *Hylobates* and *Pan*, and is inferred to reflect the habitually overhead posture of the arm in suspensory apes to assist with efficient arm elevation.”<sup>88</sup>

## Concluding Remarks and the Need for a Creationist-Paradigm Shift

Lucy was an unprecedented find for the evolutionary paleoanthropology community. For the past 50 years of paleoanthropology investigations, Lucy has remained one of the best-preserved fossil hominins for her presumed age. And so, whenever new fossils are found, the corresponding elements are always compared to Lucy's. This sets the stage for serious error if Lucy was misclassified. Consider it. If Lucy's skeleton is human and it preserves key diagnostic features indicating obligate bipedalism, as in humans—and yet it was misclassified as an *Australopithecus* species, imagine how that would impact all subsequent fossil discoveries that preserve similar features.

The impact would be devastating, leading to the systematic misclassification of fossils. I am convinced that this precisely what has happened in the field of paleoanthropology, and it has directly impacted the creation movement by creating a lot of confusion. As creationists, we have failed to recognize the fully human status of Lucy. As a result, we have unwittingly become complicit or participated in the ongoing practice of misclassifying true human bones as *Australopithecus*.

For example, creationists who fail to recognize Lucy's pelvis is human will tend to misclassify other hominin pelvises that resemble Lucy's, such as *Au. africanus* (STS 14), *Au. sediba* (MH 2), and *H. naledi*—all of which preserve true human pelvises (Figure 14). This does not help to establish clarity. It's counterproductive because it reinforces the evolutionary claim that the australopithecines exhibited human-looking postcranial anatomies that are well-suited for bipedal locomotion, which makes their “missing link” claims appear more credible, leading to widespread deception among the general public.

Generally speaking, there are two different camps in the creation community. The first group includes those who insist Lucy and her kind were an extinct, knuckle-walking quadrupedal ape. This group generally accepts the *Australopithecus* taxonomic designation of Lucy and her kind, but in order to maintain their chimp-like interpretation, they overlook the bipedal features and argue those fossils belonged to quadrupedal apes—which is easily refuted by informed evolutionists, and this is because those fossils, such as Lucy's pelvis, really do show bipedal morphologies (after all, they're human).

In the more obvious cases of mistaken identities, this group of creationists has correctly pointed out the true human identity of fossils attributed to *Au. afarensis*, such as the “Big Man” skeleton<sup>89</sup> or the fourth metatarsal found at the “First Family” site<sup>90,91</sup>. Yet, in other cases, red-herring traits (i.e., curved fingers and toes, funnel-shaped thoraxes, laterally flaring ilia, cranially oriented glenoid cavity, etc.) and false allegations about Lucy's pelvis reconstruction being fraudulent, have led this group of creationists to become blinded to the fully human status of Lucy, as well as several other misclassified bones attributed to her kind. This has resulted in an impenetrable “group think” that insists Lucy's is an extinct ape. They are so committed to this view that the possibility of Lucy being human has not occurred to them.

The second camp includes those who call themselves the “new creationists.” This group can plainly see that the other camp is overlooking or outright dismissing the bipedal features seen in the anatomy of Lucy and her kind. This group pays closer attention to key morphological features and in so doing, cannot help but acknowledge the bipedal traits seen in Lucy and the broader genus of *Australopithecus*. However, in my opinion, they go too far to the other side and have essentially conceded that evolutionists are correct

in their interpretation of *Au. afarensis* as a hominin species with obligate bipedal locomotion, a human-like postcranial skeleton, and distinctly ape-looking skulls. In essence, they have no bones to pick with the popular museum displays of Lucy. Unsurprisingly, evolutionists tend to have greater respect for this group of creationists.

This way of thinking is problematic because if we accept bipedal australopithecines that looked virtually indistinguishable from humans from the neck down, yet endowed with ape skulls, it further bolsters the evolutionary claim that *Au. afarensis* represents a credible transitional species that was on an evolutionary trajectory to become ever more like us. This is a difficult position for Christians to endorse and it results in a defeatist apologetic of the faith (read chapter 2 of *The Quest* and you'll see what I mean; though we should not disparage anyone for sharing their sincere doubts).<sup>92</sup> This evolution-friendly perspective is, nevertheless, unsupported by the fossil evidence.

This paper takes a different stance than both of these camps and argues for a simpler, more biblically intuitive (and I believe more accurate) approach. The new creationists are correct to insist those fossils preserve human-like bipedal anatomies, however, they fail to recognize that this is simply because those particular fossils *are* human—they were simply misclassified as *Australopithecus* taxa.

The approach presented in this paper is highly reliant on identifying key morphological features that are exclusively human, and in that sense, it is more scientifically disciplined than those who dismiss bipedal anatomies in order to defend the claim that Lucy was an extinct quadrupedal ape. In reality, those bipedal anatomies are the best indicators of true human bones that were misclassified. This new perspective also provides a stronger biblical apologetic because it does not acquiesce to the evolutionary interpretations of bipedal australopithecine species as stratigraphic precursors to *Homo*, as the new creationists claim.

A compelling case can be made that the hypodigm of *Au. afarensis* from 3-4 million years ago (according to conventional age assignments), as well the *Australopithecus* genus more broadly, includes true human bones that were misclassified—far more than has been previously recognized. Lucy is just one of many. This supports the biblical model of coexistence far deeper into the hominin fossil record, which falsifies the ape-to-man model. Obviously, the discovery of true human fossils, such as A.L. 129-1 (3.4 Ma), and partial human skeletons, like Big Man (3.6 Ma) and Lucy (3.2 Ma), dating prior to the origin of the genus *Homo* (2.5-2.8 Ma), should be impossible in view of the prevailing ape-to-man model.

## Appendix

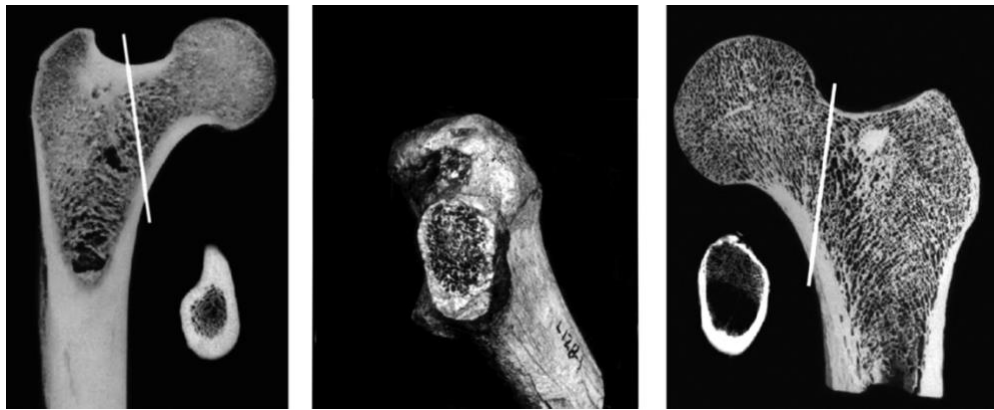
### *A Pygmy Human Proximal Femora (A.L. 129c and A.L. 128-1)*

Other findings further corroborate the presence of small-bodied humans in the Hadar formation. In October of 1973,<sup>93</sup> two proximal femurs were recovered near the A.L. 129 knee joint; one “lay almost next to the knee joint” (A.L. 129c) and the other was fifty feet away (A.L. 128-1) “and had carnivore tooth marks on it, suggesting it had been dragged off to be eaten.”<sup>94</sup> Obviously, there association can be questioned, yet Johanson maintained they belong to the same individual as the owner of the knee joint since they were the right size and found in the same stratigraphic layer—one of which was found right next to the knee joint. Whatever the case may be, the fragments preserved the upper end of the femur yet

lacked the heads and necks. The left proximal femur (A.L. 128-1) was better preserved with the shaft broken ~38.0 mm below the lesser trochanter.<sup>95</sup> A cross-section view of the preserved part of the femur neck provides information relating to load bearing during locomotion, and these appear distinct when compared to chimpanzee (Figure 18). An X-ray image was taken by Lovejoy, which supports the human identity of the A.L. 128 femur:

“X-rays show dramatic differences between the femur necks of a chimpanzee, on the left, and a modern human. The chimpanzee has a thick layer of dense bone that forms a bony ridge at the top. This design withstands the physical forces that a chimp encounters while climbing trees. The human design, with more spongy bone inside and a thick outer layer at the bottom, withstands the forces of two-legged walking. The Hadar fossils are almost identical to the human pattern.”<sup>96</sup>

Researchers reporting in an orthopedics research journal examined the ossification pattern seen in the A.L. 128 proximal femur, originally described by Lovejoy, and agreed with his assessment.<sup>97</sup>



**Figure 18.** A comparison of the ossification pattern in the femoral neck of chimp (left), *Au. afarensis*, A.L. 128-1 (center), and *H. sapiens* (right). The ossification pattern matches human femora. Images originally from: Lovejoy (2005)<sup>98</sup> and Ohman (1997);<sup>99</sup> combined from: T. Hogervorst et al. (2009).

### ***Lucy's Human Talocrural Joint***

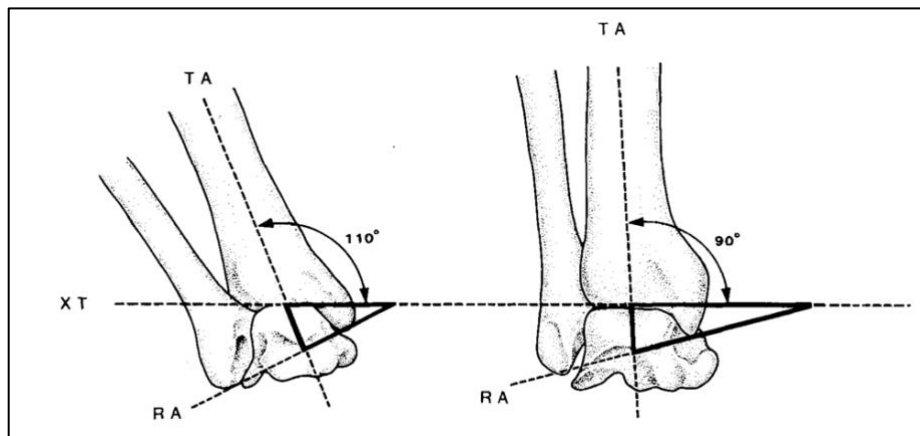
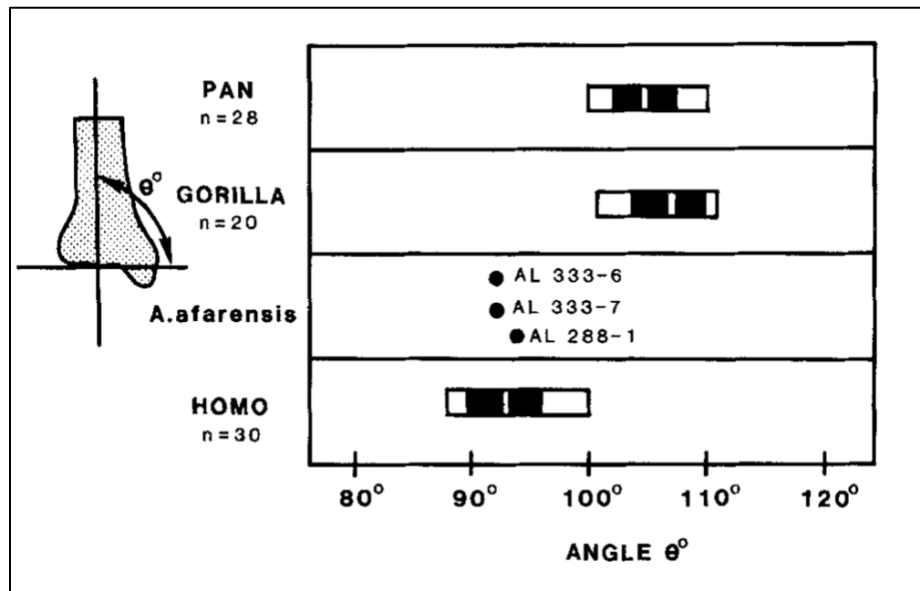
LB 1 preserves numerous foot bones, including a nearly complete left foot. The foot is human with a rigid midfoot and adducted hallux, though some traits are unusual. The navicular bone indicates LB 1 was flat-footed and the toes are curved. The navicular bone is described in Hobbit (and *H. naledi*) as looking more primitive or “closer to those of great apes.”<sup>100</sup> However, since the overall morphology and function of the foot is clearly of a human biped, the navicular bone and curved toes and can be regarded as peculiar traits in a genetically isolated population.

The foot of Lucy preserves a proximal and middle phalanx and a talus. No other bones of the foot were recovered. The two toe bones are relatively long and curved compared to modern humans, yet shorter and less curved than a chimpanzee. Since curved fingers and toes are present in human specimens, including LB 1, *H. naledi*, and *H. luzonensis*—this cannot be considered a diagnostic trait for distinguishing apes from humans.

Another way that Lucy is similar to LB 1 is asymptomatic flat feet, as indicated by the tibia.<sup>101</sup> However, this cannot be considered a “primitive” trait since modern humans are known to have similar conditions, as researchers acknowledge: “Despite the importance of the arch to foot biomechanics in modern humans, some people can walk normally and pain free on asymptomatic, physiologic flat feet.”<sup>102</sup>

Lucy’s talus was recovered together with the distal end of a fibula and a tibia. The ankle joint, technically referred to as the talocrural joint, is formed by the articulation of the distal tibia and fibula with the talus. The shape of Lucy’s talus is robust and morphically similar to humans and different from apes,<sup>103</sup> only it’s smaller in size for an adult, which is consistent with the pygmy human hypothesis. When describing the talocrural joint of Lucy and comparing it to great apes and modern *H. sapiens*, Latimer et al. (1987) state, “In every functionally significant feature examined the A.L.288-1 talocrural joint is fully bipedal.”<sup>104</sup>

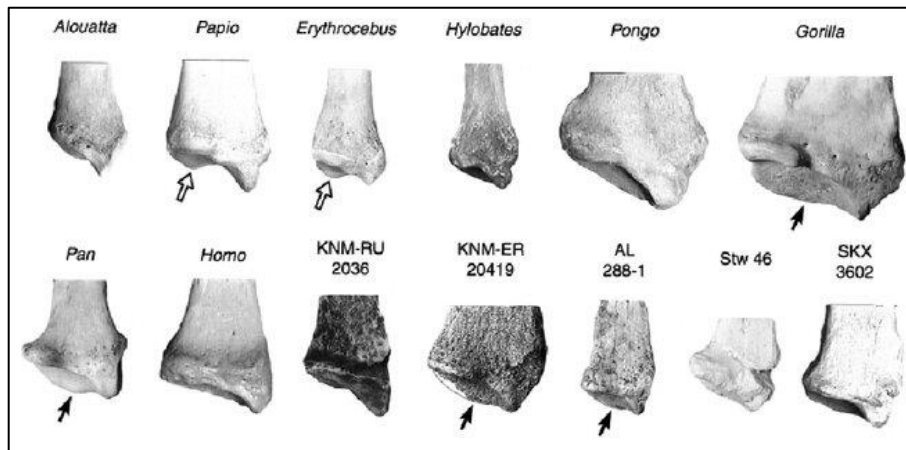
One particular diagnostic feature they examined was the angle between the midline of the tibial shaft and the inclination of the distal articular surface, shown below (Figure 19). They note that “there is no overlap between pongid and hominid ranges, and this angle is nearly perpendicular in all hominin tibiae.”<sup>105</sup> Other diagnostic features of the human ankle seen in Lucy’s talocrural joint are described in their paper.



**Figure 19.** Upper: The midline of the tibial shaft is nearly perpendicular to a midcoronal plane along the distal articular surface. In addition to Lucy's, specimens from the "First Family" (A.L. 333-6 and -7), fall in line with the mean value of the human range. The human configuration of these specimens is consistent with the composite human foot found from the same site, as well as Johanson's original description of the AL 333 fifth metatarsal and the original attribution of the First Family collection of bones to *Homo* (see ref. 78 for a lecture describing these fossils). Vertical white line = mean; black rectangle =  $\pm 1$  S.D.; white bar = total range. Lower: The human ankle configuration shown on the right forms a nearly perpendicular angle with the midshaft of the tibia and the distal articular surface, whereas in pongid an obtuse angle is formed. See Fig. 8 in Latimer et al. (1987) for a more detailed description.

### ***Lucy's Distal Radii Indicates Knuckle-walking?***

Richmond and Strait (2000)<sup>106</sup> have claimed Lucy's preserves distal radii indicating knuckle-walking locomotor behavior. This observation is based on a distal projection and a medially extended dorsal ridge (Figure 20; see also Fig. 3 in Richmond and Strait, 2020). Creationists have argued this is decisive evidence Lucy was a quadrupedal ape.<sup>107</sup>



**Figure 20.** Distal radii of various taxa compared to Lucy, A.L. 288-1. Researchers debate whether the distal projection (arrows) should be considered diagnostic of knuckle-walking. From: Richmond and Strait (2001).

However, Crompton et al. (2008) have challenged this interpretation.<sup>108</sup> These researchers suggest that distal projection and related morphometrics may be considered ambiguous or non-diagnostic since they overlap with non-knuckle walking apes, such as orangutan (see Fig. 2 in Richmond and Strait, 2000). In support of this criticism, other studies have acknowledged features in Lucy's radii that are present in orangutan and hylobatids, which have adducted wrist posture, "the reverse of the condition in panins and gorillines."<sup>109</sup> Thus, the evidence of knuckle-locking wrists based on Lucy's distal radii is inconclusive, at best, and should not be given greater weight than the numerous diagnostic traits found in Lucy's skeleton that are unambiguously human.

Even granting for the sake of argument this feature is truly diagnostic of knuckle-walking, how can it be considered compatible with a human-like pelvis, femur, and talocrural joint, all of which indicate a human

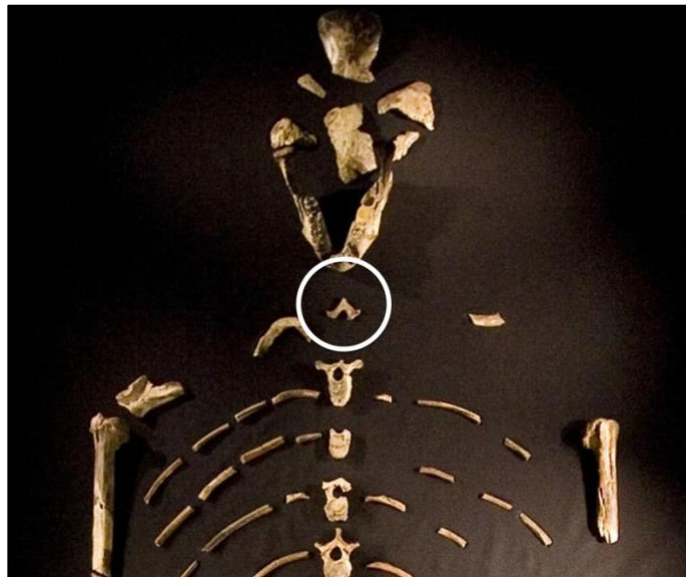
bipedal gait in Lucy? Those would be an unprecedented combination of traits, representing two distinct locomotor patterns that are functionally incompatible in a single skeleton.

### ***Lucy's Vertebral Column and a Misplaced Baboon Vertebra***

Included with Lucy's skeleton are 9 vertebrae. Since the discovery of Lucy, the exact placement and continuity of these vertebrae within the vertebrae column has been questioned. A more recent study has recognized that one of the vertebrae (A.L. 288-1am) was smaller and morphologically distinct from the others. These researchers found that it belonged to a *Theropithecus* (a baboon genus) that "escaped notice for 40 years." Meyer et al. (2015) write:

"Quantitative analyses situate this vertebra within the genus *Theropithecus*, which today is solely represented by the gelada baboon but was the most abundant cercopithecoid in the KH-1s deposit at Hadar where Lucy was discovered."<sup>110</sup>

The authors reassured that the remaining vertebrae can be confidently attributed to Lucy. However, the misclassified baboon vertebrae, led to a re-ordering of the sequence of Lucy's preserved elements. They concluded that the remaining thoracic vertebrae form a continuous series from T6-T11. In addition, the two preserved lumbar vertebrae were reassigned (Table 1).



**Figure 21.** A baboon vertebrae element mistakenly included with Lucy's skeleton (white circle).



**Table 1.** Revision of the assignment locations of the nine vertebrae elements attributed to Lucy, now excluding the misclassified baboon element (A.L. 288-1am). From: Meyer et al. (2015).

A.L. 288-1	Johanson <sup>a</sup>	Cook et al.	This study
am	T1/2/3/4	T3/T4	N.H. <sup>b</sup>
ae/ah	T6	T6	T6
af	T8	T7	T7
ag/aj	T9	T8	T8
ad	T10	T10	T9
ac	T11	T11	T10
ai	T12	T12	T11
ab	N/A	L3/L4	L2
aa/ak/al	L3	L2	L3

<sup>a</sup> Johanson et al. (1982). Ranges are sometimes given, but the preferred element diagnosis is listed here.

<sup>b</sup> Non-hominin: we refer the neural arch A.L. 288-1am to fossil *Theropithecus darti*.

### *Is Lucy a Chimera of Ape and Human Fossils?*

Given the fact that a baboon bone “escaped notice for 40 years” and was accidentally included as part of Lucy’s skeleton, it is entirely possible that other seemingly out of place bone fragments were mistakenly included as well. However, so far, no additional misidentified bones have been recognized. All skeletal elements that preserve unambiguous diagnostic features appear distinctly human. Nevertheless, this is at least possible given the large volume of sediment that was excavated and the high concentration of non-human fossils buried in the Hadar formation.

The Hadar formation has been described as bearing sediments that are “littered with fossils,” including numerous primate specimens.<sup>111</sup> Lucy was recovered from the Kada Hadar (KH) member, the highest of three members that make up the Hadar Formation. Among the remains that were immediately found on November 24, 1974, were the right proximal ulna (forearm), occipital fragment, femur, ribs, pelvis, and lower jaw. However, it wasn’t until at least a few weeks later that the remaining bones were screened out of the excavated sediment. Johanson’s article in *National Geographic* (1976) recounts:

“So as not to miss any bit of Lucy, workmen sift 50 square meters [540 square feet] of hillside 288, where her bones were found. Here they sack gravel to be washed at a riverside. During two fall seasons, expedition members screened more than twenty tons by hand and discovered hundreds of other fragments that may fit into Lucy’s skeleton.”<sup>112</sup>

Arizona State University’s Institute of Human Origins webpage, details this process of excavating and sifting out the remaining bones, stating:

“Within moments, he spotted a right proximal ulna (forearm bone) and quickly identified it as a hominid. Shortly thereafter, he saw an occipital (skull) bone, then a femur, some ribs, a pelvis, and the lower jaw. Two weeks later, after many hours of excavation, screening, and sorting,

several hundred fragments of bone had been recovered—47 of which formed a small fossil skeleton...”<sup>113</sup>

It was during this screening processes that “hundreds of other fragments” were recovered, from which Johanson wrote, “may fit into Lucy’s skeleton.” This is probably how the baboon vertebrae bone was accidentally included as part of Lucy. It is also possible (though I personally doubt this) that additional non-human primate bones were recovered and mistakenly included in Lucy’s skeleton.

### ***Are “Ape-like” Reconstructions of Lucy’s Skull Legitimate?***

Reconstructions of Lucy’s skull appear distinctly ape-like in museum exhibits. They are inspired more by evolutionary preconceptions than actual fossil evidence. For instance, the skull of Lucy displayed in the Smithsonian National Museum of Natural History (NMNH) was made as a composite—the few preserved pieces of bone were combined with the distinctly ape-like male skull, A.L. 444-2, which was found from a separate Afar locality, completely unassociated with a post-cranial skeleton. The artist responsible for the reconstruction, John Gurche, explains:

“How can we coax a face from her shattered bits? Although her preserved skull fragments are not complete enough to allow reconstruction of her skull, there are more complete fragments of female crania that can be combined with Lucy’s fragments into a composite skull reconstruction. The accuracy of such a composite can be assessed as more female crania are discovered and published (one such skull, A.L. 882—the reverse of Lucy’s specimen number—is now under study, and researchers have begun to publish their findings). In order to walk the reader through the details of an *A. afarensis* head reconstruction based on a more complete skull from a single individual, I’ll switch to the one based on the male skull, A.L. 444-2, the most complete skull for which research has been published for the species. The fleshing out of the composite female skull [Lucy’s] proceeded, similarly but with more maybes.”<sup>115</sup>

The male specimen A.L. 444-2 was discovered 18 years after Lucy, as Gurche comments, “*A. afarensis* went headless for twenty years”. And so, most reconstructions of Lucy’s skull, including the one done by the NMNH artist, were completed before this specimen was recovered/assembled, using the very limited fossil material available at the time. I don’t have a bone to pick with the artist on what he did. He made the most of what he had available; the real issue has to do with the taxonomic assignment of Lucy’s skeleton—and that was decided by Donald Johanson and the paleoanthropology community. Why was Lucy’s distinctly human-looking skeleton assigned to a member of the species, *Au. afarensis*, to begin with? Those few isolated fragments of Lucy’s skull could have been assembled using far less imagination to appear human, perhaps similar to the small-bodied human, LB 1, with nearly equivalent brain size.

### ***Lucy’s Mandible***

Lucy’s mandible has non-projecting chin as seen in *H. floresiensis*, *H. naledi*, and the pygmy human sample from Palau, Micronesia.<sup>116</sup> Therefore, this feature considered alone is insufficient evidence to attribute the mandible to *Australopithecus*. Future work will involve a more thorough analysis of Lucy’s

mandible and teeth, including comparisons to other mandibles from Hadar and Laetoli that were originally considered *Homo* and later assigned to *Au. afarensis* (e.g., LH 4).

## References

1. Königsson, L.K., Sundström, S., *Current Argument on Early Man: Proceedings of a Nobel Symposium Organized by the Royal Swedish Academy of Sciences and Held at Björkborns Herrgård, Karlskoga, Sweden, 21-27, May, 1978*. Royal Swedish Academy of Sciences, 1980.
2. Johanson, D. and White T.D., A Systematic Assessment of Early African Hominids, *Science* 203(4378):321-330, 1979.
3. Menton, D., *Creation Library Series: Lucy—She’s No Lady!*, Hebron, Answers in Genesis, 2003. DVD.
4. Oard, M.J., More evidence *Australopithecus* was an extinct ape, *Journal of Creation* 27(2):14 Aug 2013. <https://creation.com/more-evidence-australopithecus-an-extinct-ape>
5. Line, P., Lucy at 50 has not aged well, *Creation* 46(4), Oct 2024. <https://creation.com/en-us/articles/lucy-at-50>
6. Brummel, P. The True Story of Lucy’s Knee, New Creation Blog, Dec 2023. <https://newcreation.blog/the-true-story-of-lucys-knee/>
7. Murdock, M., These apes were made for walking: the pelves of *Australopithecus afarensis* and *Australopithecus africanus*, *Journal of Creation* 20(2), 2006. [https://creation.com/images/pdfs/tj/j20\\_2/j20\\_2\\_104-112.pdf](https://creation.com/images/pdfs/tj/j20_2/j20_2_104-112.pdf)
8. Meyer M.R. *et al.*, Lucy’s back: Reassessment of fossils associated with A.L. 288-1 vertebral column, *J Hum Evol* 85:174-180, 2015.
9. Johanson, D., Ethiopia Yields First “Family” of Early Man, *National Geographic*, 150(6): Dec 1976.
10. Johanson, D., *Nova, In Search of Human Origins (Part 1)*, PBS Airdate: June 3, 1997. Transcript at <http://www.pbs.org/wgbh/nova/transcripts/2106hum1.html>. See also: <https://iho.asu.edu/about/lucys-story>
11. Lovejoy, C., The natural history of human gait and posture, Part 1. Spine and Pelvis, *Gait and Posture* 21(1):95-112, 2005.
12. Johanson, D., Johanson, L., and Edgar, B., *Ancestors: In Search of Human Origins*, Villard Books, New York, 1994, p.70-71.
13. Whitehead, P.F., Sacco, W.K., and Hochgraf, S.B., *A Photographic Atlas for Physical Anthropology*, Englewood: Morton Publishing Company, 2005.
14. Lovejoy, O., and McCollum, M.A., Spinopelvic pathways to bipedality: why no hominids ever relied on a bent-hip-bent-knee gait, *Philos Trans R Soc Lond B Biol Sci* 365(1556), 2010.
15. Whitehead, P.F. *et al.*, ref. 13, p.184.
16. Schmid, P., Ein Rekonstruktion des Skelettes von A.L. 288-1 (Hadar) und deren Konsequenzen, *Folia Primatol* (40)283e306, 1983.
17. Häusler M. and Schmid P., Comparison of the pelves of Sts 14 and AL 288-1: implications for birth and sexual dimorphism in australopithecines, *J Hum Evol* 29:363-383, 1995.

18. Lovejoy C.O., A reconstruction of the pelvis of A.L. 288-1 (Hadar Formation, Ethiopia). *Am J Phys Anthropol.*, 50, 1979.
19. Tague, R.G. and Lovejoy, C.O., A.L. 288-1—Lucy of Lucifer: gender confusion in the Pliocene, *J Hum Evol* 35(1):75-94.
20. Brassey, C.A., O’Mahoney, T.G., Chamberlain, A.T., and Sellers, W.I., A volumetric technique for fossil body mass estimation applied to *Australopithecus afarensis*, *J Hum Evol* 115, 2018.
21. Pers. comm. with O’Mahoney, T.G., coauthor of Brassey et al., ref 20. O’Mahoney was responsible for the digital reconstruction of Lucy’s pelvis; Feb 28, 2025.
22. Brassey et al., ref 20: Lucy A.L. 288-1 reconstructed pelvis:  
<https://doi.org/10.6084/m9.figshare.4746886.v1>
23. Mehlert, A.W., *Australopithecus* and *Homo habilis*—pre-human ancestors? *Journal of Creation* 10(2):219-240, Aug 1996. <https://creation.com/australopithecus-and-homo-habilis>
24. Miller, C.K., and DeSilva, J.M., A review of the distal femur in *Australopithecus*, *Evolutionary Anthropology* 33(1), 2023.
25. Miller et al., ref 24.
26. Johanson et al., ref. 12.
27. Junger’s reaction was documented in a stock photo description: <https://www.alamy.com>. For a similar description, see Jungers et al., ref. 28.
28. Jungers, W.L., Larson, S.G., Harcourt-Smith, W., Morwood M.J., Sutikna, T., Due Awe, R., Djubiantono, T., et al., Descriptions of the Lower Limb Skeleton of *Homo floresiensis*, *J Hum Evol* 57, 2009.
29. Jacob, T. *et al.*, Pygmoid Australomelanesian *Homo sapiens* skeletal remains from Liang Bua, Flores: Population affinities and pathological abnormalities, *Proc Natl Acad Sci, USA* 103(36):13421-13426, 2006.
30. Hershkovitz, I. *et al.*, Comparative skeletal features between *Homo floresiensis* and patients with primary growth hormone insensitivity (Laron syndrome), *Am J Phys Anthropol* 134(2):198-208, 2007.
31. Berger, L.R. *et al.*, Small-bodied humans from Palau, Micronesia, *PLOS ONE* 3(3):e1780, 2008.
32. Jungers, W.L., Grabowski, M., Hatala, K.G., and Richmond, B.G., The evolution of body size and shape in the human career, *Phil Trans R Soc B*, 371:20150247, 2016.
33. Jungers et al., ref 32.
34. Kimbel, W.H. and Delezen, L.K., “Lucy” Redux: A Review of Research on *Australopithecus afarensis*, *Yearbook of Physical Anthropology* 140(S49), 2001.
35. Sylvester A.D., Merkl, B.C., and Mahfouz M.R., Assessing A.L. 288-1 femur length using computer-aided three-dimensional reconstruction, *J Hum Evol* 55(4):665-71, 2008.
36. Jungers et al., ref. 32.
37. Brassey et al., ref. 22.
38. Brassey et al., ref. 22.
39. Kimbel et al., ref. 34: “Ohman (1986) demonstrated that, as in *H. sapiens*, the *A. afarensis* first rib has a single articulation with the first thoracic vertebra, as opposed to a “bivertebral” articulation, with the superior portion of the first thoracic centrum and the inferior portion of the

seventh cervical centrum, as is observed in all nonhuman primates.” See also: Johanson, D.C., et al., Morphology of the Pliocene Partial Hominid Skeleton (A.L. 288-1) From the Hadar Formation, Ethiopia, *Am J Phys Anthro*, 57: 403-45, 1982: “The specimen is of modern human form.”

40. Berger, L.R., et al., *Homo naledi*, a new species of the genus *Homo* from the Dinaledi Chamber, South Africa, *eLife* 4:e09560, 2015, p. 18.
41. Tattersall, I., *The Strange Case of the Ricketty Cossack*, Palgrave Macmillan, New York, NY, pp. 203-204, 2015.
42. Hershkovitz, I. et al., Comparative Skeletal Features Between *Homo floresiensis* and Patients with Primary Growth Hormone Insensitivity (Laron Syndrome), *Am J Phys Anthropol* 134:198-208, 2007.
43. Hershkovitz et al., ref. 42.
44. Latimer, B.M., Lovejoy, O.C., Linda S., and Haile-Selassie, Y., The Thoracic Cage of KSD-VP-1/1, In: Haile-Selassie, Y., and Su, D.F., (eds.), Chapter 7, *The Postcranial Anatomy of Australopithecus afarensis: New Insights from KSD-VP-1/1*, Vertebrate Paleobiology and Paleoanthropology, 2016. These researchers argue *Australopithecus* (including Lucy) had a more bell-shaped thorax shape, similar to other pre-*Homo sapiens* like Neanderthals, with “some amount of lateral flaring in the lower thorax.” They explain further that the barrel vs. funnel shape concept is an “overly simplistic dichotomy.”
45. Johanson, D.C. and Taieb, M., Plio-Pleistocene hominid discoveries in Hadar, Ethiopia, *Nature* 260(5549):293-7, 1976: “The cranium is not sufficiently complete to estimate cranial capacity.”
46. Gunz, P. et al., *Australopithecus afarensis* endocrasts suggest ape-like brain organization and prolonged brain growth, *Science Advances* 6:14, 2020. “We used multivariate statistics based on detailed measurements of the endocranial surface in apes ( $N = 122$ ) to estimate EV in the best-preserved *A. afarensis* fossil crania.”
47. Kubo, D., Kono, R.T., and Kaifu, Y., Brain size of *Homo floresiensis* and its evolutionary implications, *Proc R Soc B* 280(1760), 2013
48. Falk, D. et al., The brain of LB1, *Homo floresiensis*, *Science* 308(5719):242-245, 2005.
49. DeSilva, J.M., Lucy’s Flat Feet: The Relationship between the Ankle and the Rearfoot Arching in Early Hominins, *PLOS ONE*, 5(12), 2010.
50. Henneberg, M. et al., Evolved developmental homeostasis disturbed in LB1 from Flores, Indonesia, denotes Down syndrome and not diagnostic traits of the invalid species *Homo floresiensis*, *Proc Natl Acad Sci, USA* 111(33):11967-11972, 2014.
51. Lucy preserves a proximal and middle pedal phalanx and a manual proximal phalanx. They are described as long and curved, yet not to the degree observed in apes.
52. Stringer, C., Human evolution: Smaller remains still pose big problems, *Nature* 514(7523):427-9, 2014.
53. Hawks, J. et al., New fossil remains of *Homo naledi* from the Lesedi Chamber, South Africa, *eLife*, 2017.
54. Feuerriegel, E.M. et al., The upper limb of *Homo naledi*, *J Hum Evol* 104:155-173, 2017.
55. Berger et al., ref. 31.
56. Berger et al., ref. 31. See also: Rupe C. and Sanford J., *Contested Bones*, ch. 14, for additional studies supporting genetic isolation and inbreeding in *Homo* taxa, including *H. naledi* and LB 1.

57. Miller et al., ref. 24.
58. Miller et al., ref. 24.
59. Johanson ref. 45; see also: Johanson, ref. 9.
60. A post-flood interpretation is based the observation that the Hadar findings are associated with localized volcanic deposits and African fauna resembling modern extant taxa from the region.
61. Lague, M., Another look at shape variation in the distal femur of *Australopithecus afarensis*: implications for taxonomic and functional diversity at Hadar, *J Hum Evol* 42(5):609-626, 2002.
62. Johanson, D., The Paleoanthropology of Hadar, Ethiopia, *Competes Rendus Palevol* 16(2):140-154, 2017.
63. Lague, ref. 61.
64. Schwartz, J.H., *Defining Hominidae*, 2014, in: *Handbook of Paleoanthropology*, Springer-Verlag Berlin Heidelberg, pp.1-39.
65. O'Micks, J., *Homo naledi* Probably Not Part of the Human Holobaramin Based on Baraminic Re-Analysis Including Postcranial Evidence, *Answers Research Journal* 9, Oct 2016.  
<https://answersresearchjournal.org/homo-naledi-not-human/>
66. Arsuaga, J. et al., A complete human pelvis from the Middle Pleistocene of Spain, *Nature* 399:255-258, 1999.
67. Churchill, S.E. and VanSickle, C., Pelvic Morphology in *Homo erectus* and Early *Homo*, *The Anatomical Record* 300:964-977, 2017.
68. Henneberg, M. et al., Evolved developmental homeostasis disturbed in LB1 from Flores, Indonesia, denotes Down syndrome and not diagnostic traits of the invalid species *Homo floresiensis*, *Proc Natl Acad Sci, USA* 111(33):11967-11972, 2014.
69. VanSickle, C. et al., *Homo naledi* pelvic remains from the Dinaledi Chamber, South Africa, *J Hum Evol*, 2017.
70. Hershkovitz, I. et al., Comparative Skeletal Features Between *Homo floresiensis* and Patients with Primary Growth Hormone Insensitivity (Laron Syndrome), *Am J Phys Anthropol*, 134:198-208, 2007.
71. Rosenberg, K.R. et al., Evolution of the Human Pelvis, *The Anatomical Record*, 300:789-797, 2017.
72. Tomkins, J., *Homo naledi*: Another Failed Evolutionary Ape-Man, Dec 31, 2019.  
<https://www.icr.org/article/homo-naledi-another-failed-evolutionary-ape-man/>
73. VanSickle et al., ref 67. “The degree of lateral flare of the *H. naledi* ilium resembles that of *A. africanus* (i.e., Sts 14, Sts 65, and StW 431) and *A. afarensis* (i.e., A.L. 288-1; ...”
74. Mitchell, E., Is *Homo naledi* a New Species of Human Ancestor? Sep 12, 2015.  
<https://answersingenesis.org/human-evolution/homo-naledi-new-species-human-ancestor/>
75. Détroit F. et al., A new species of *Homo* from the Late Pleistocene of the Philippines, *Nature* 568, 181–186, 2019.
76. Kivell T.L., Evidence in hand: recent discoveries and the early evolution of human manual manipulation. *Phil Trans R Soc B* 370: 20150105, 2015. <http://dx.doi.org/10.1098/rstb.2015.0105>
77. Ward, C.V. et al., New postcranial fossils of *Australopithecus afarensis* from Hadar, Ethiopia (1990-2007), *J Hum Evol*, 63(1):1-51, 2012.

78. Several hand and foot fossils preserving diagnostic human features. recovered from site A.L. 333 that Johanson originally attributed to *Homo*, are identified and described in the following video lecture: <https://youtu.be/-UrnA8MpYK4?t=2514>
79. Willis, D., *The Leakey Family: Leaders in the Search for Human Origins*, New York: Roundhouse Publishing Ltd., 1992, p. 100. “Johanson also thought that the First Family from Ethiopia was *Homo*, just as Tim White thought the Laetoli hominids were *Homo*. This belief supported the Leakey’s theories. But after White had his disagreement with Richard Leakey and teamed up with Don Johanson, he changed his mind about the genus the fossil belonged to, and then he changed Johanson’s mind.”
80. Aiello, L., and Dean, C., *An Introduction to Human Evolutionary Anatomy*, Academic Press, Harcourt Brace Jovanovich, 1990, p. 353.
81. The distinctly human hand recovered from the arm block “refits perfectly” with the scapular fragment block, confirming both parts are human. See Rupe C., and Sanford J., *Contested Bones*, 2019 update, p. 185 and Fig. 6 on p. 188 revealing the human hand proportions of MH 2. See also: Rak, Y., Been, E., and Hylander, W., One hominin taxon or two at Malapa Cave? Implications for the origin of *Homo*, *S Afr J Sci* 117(5/6), 2021.
82. Churchill S.E. *et al.*, Special Issue: The Shoulder, Arm, and Forearm of *Australopithecus sediba*, *PaleoAnthro- pology*, 2019. See also Y. Rak, E. Been, and W. Hylander, One hominin taxon or two at Malapa Cave? Implications for the origin of *Homo*, *South African Journal of Science*, 117(5/6), 2021.
83. L. Aiello and C. Dean, *An Introduction to Human Evolutionary Anatomy*, Academic Press, Harcourt Brace Jovanovich, 1990, p. 354.
84. Dalton, R., Africa’s next top hominid: ancient human relative could walk upright, *Nature News*, June 21 2010. <https://www.nature.com/articles/news.2010.305>
85. Haile-Selassie Y. *et al.*, An early *Australopithecus afarensis* postcranium from Woranso-Mille, Ethiopia, *Proc Natl Acad Sci, USA* 107(27):12121-12126, 2010.
86. Inouye, S.E. and Shea, B.T, What’s your angle? Size correction and bar-glenoid orientation in “Lucy” (A.L. 288-1), *International Journal of Primatology* 18, 1997.
87. Lordkipanidze, D. *et al.*, Postcranial evidence from early *Homo* from Dmanisi, Georgia, *Nature* 449, 2007.
88. Feuerriegel, E.M. *et al.*, The upper limb of *Homo naledi*, *J Hum Evol* 104, 2017.
89. Line, P., He ain’t my brother: no apparent family ties between Big Man and Lucy, Sep 23, 2010. <https://creation.com/big-man-and-lucy>
90. Carl, W., ‘Lucy walked upright!’ (or did she?) One tiny bone ignites evolutionary fervour, Feb 17, 2011. <https://creation.com/lucy-walked-upright>
91. Thomas, B., ‘Lucy’s’ New Foot Bone is Actually Human, *Acts & Facts*, Mar 31, 2011. <https://www.icr.org/article/lucys-new-foot-bone-actually-human>
92. C. Wood, *The Quest: Exploring Creationist’s Hardest Problems*, Nashville: New Creation, 2018.
93. Johanson ref. 45.
94. Johanson D.C. and Edey M.A., *Lucy: The Beginnings of Humankind*, Simon & Schuster, New York, p.160, 1981.
95. Johanson ref. 45.

96. Johanson et al., ref. 12.
97. Hogervorst, T., Bouma, H.W., and de Vos, J., Evolution of the hip and pelvis, *Acta Orthopaedica*, 80, sup336, 2009.
98. Lovejoy, ref. 11.
99. Ohman, J.C., Krochta, T.J., Lovejoy, C.O., Mensforth, R.P., and Latimer, B., Cortical Bone Distribution in the Femoral Neck of Hominoids: Implications for the Locomotion of *Australopithecus afarensis*, *American Journal of Physical Anthropology*, 104:117-131, 1997.
100. Sorrentino R., et al., Morphological and evolutionary insights into the keystone element of the human foot's medial longitudinal arch, *Communications Biology* 6(1061), 2023.
101. DeSilva, J.M., and Throckmorton Z.J., Lucy's Flat Feet: The Relationship between the Ankle and Rearfoot Arching in Early Hominins, *PLOS ONE*, 5(12):e14432, 2010.
102. DeSilva, ref. 101.
103. <https://elucy.org/companant/talus/>
104. Latimer, B., Ohman, J.C., and Lovejoy, O., Talocrural Joint in African Hominoids: Implications for *Australopithecus afarensis*, *American Journal of Physical Anthropology*, 74:155-175, 1987.
105. Latimer et al., ref 104.
106. B.G. Richmond, D. Begun, and D.S. Strait, Origin of Human Bipedalism: The Knuckle-Walking Hypothesis Revisited, *Am J Phys Anthro*, 2001.
107. Menton, D. and Mitchell, E., A Look at Lucy's Legacy, *Answers in Depth*, Nov 24, 2015.  
<https://answersingenesis.org/human-evolution/lucy/a-look-at-lucys-legacy/>
108. Crompton, R.H., Vereecke, E.E., and Thorpe, S.K.S., locomotion and posture from the common hominoid ancestor to fully modern hominins, with special reference to the last common panin/hominin ancestor, *J Anat*, 212, 2008, pp.501-543.
109. Heinrich, R.E. et al., Hominid Radius from the Middle Pliocene of Lake Turkana, Kenya, *Am J Phys Anthro*, 92:139:-148 (1993).
110. Meyer, M.R. et al., Lucy's back: Reassessment of fossils associated with A.L. 288-1 vertebral column, *J Hum Evol* 85:174-180, 2015.
111. Frost, S. and Delson, E., Fossil Cercopithecoidea from the Hadar Formation and surrounding areas of the Afar Depression, Ethiopia, *J Hum Evol*, 43, 687-748, 2002.
112. Johanson, ref. 9.
113. Lucy's Story, Institute of Human Origins, Arizona State University:  
<https://iho.asu.edu/about/lucys-story>
114. Berger, ref. 31.
115. J. Gurche, *Shaping Humanity: How Science, Art, and Imagination Help us Understand our Origins*, New Haven and London: Yale University Press, 2013, p. 44.
116. Berger, ref. 31